

IMAGING MISTAKES FOR THE ON-CALL RADIOLOGIST: CAN WE AVOID THEM?

HENRIQUE RODRIGUES, CÉLIA ANTUNES, FILIPE CASEIRO-ALVES

Learning objectives:

- Expose to others difficult situations to with which I was confronted in urgency shift, and teach then throughout my mistakes and successes.

Background:

- Urgency department is a stressful place for a young radiologist; we face unexpected situations that need a rapid response, even when they are not true emergencies. Sometimes we are alone, and have to decide quickly under the pressure of anxious clinicians.
- So we decided to share a variety of cases of personal experience, to help others we faced with similar situations.
- Traumatic pathology was excluded from the scope of this presentation

Structure

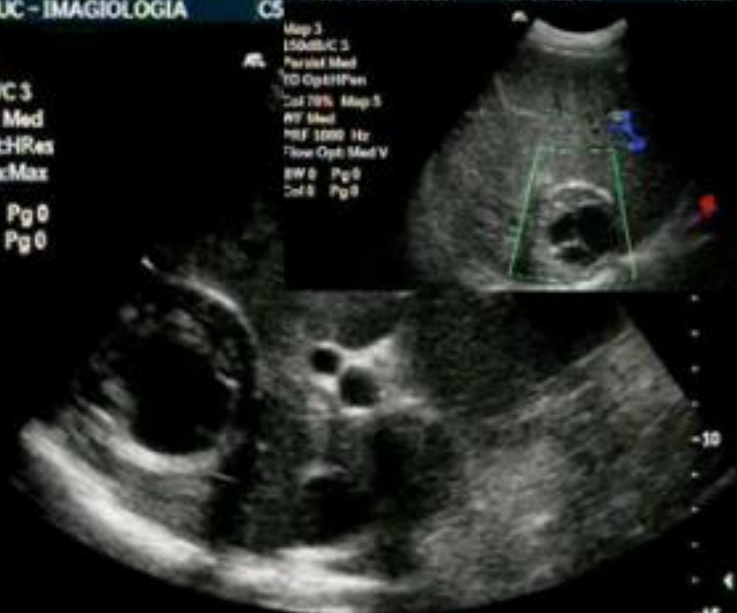- We want to show a set of cases for the various areas of the gastrointestinal tract, in the form of problem cases, emphasizing image interpretation, and doubts we had.
- Some are of uncommon presentation, in order to draw attention to the challenges faced by the radiologist.

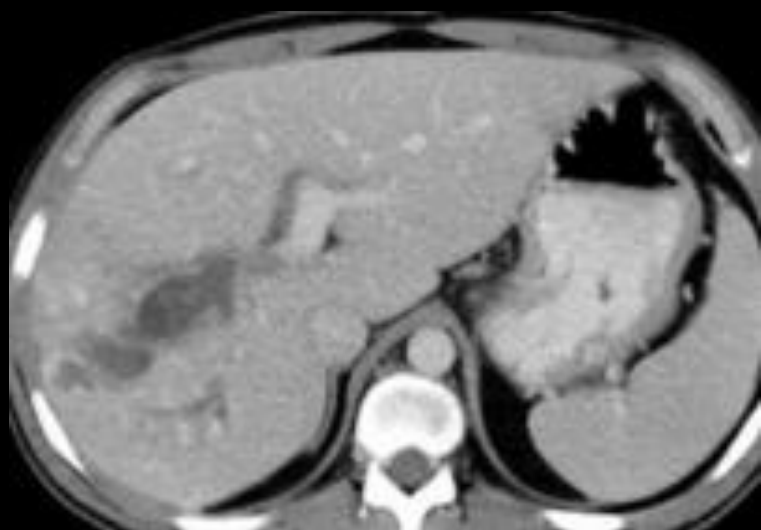
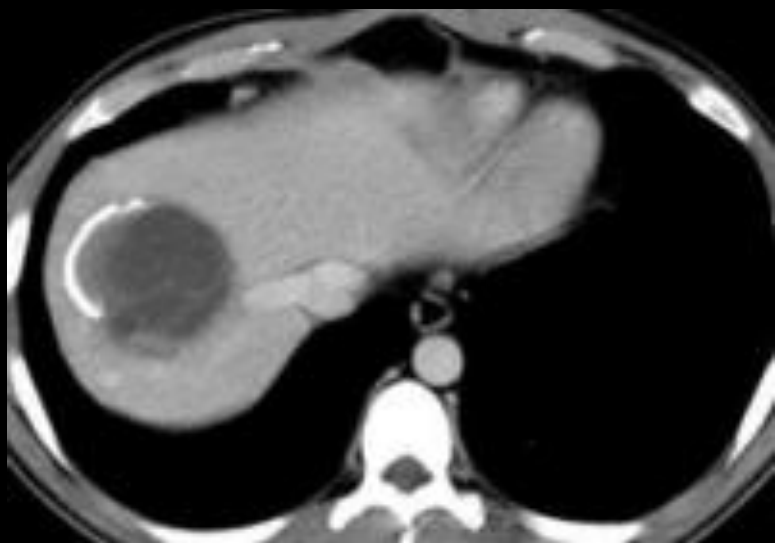
LIVER

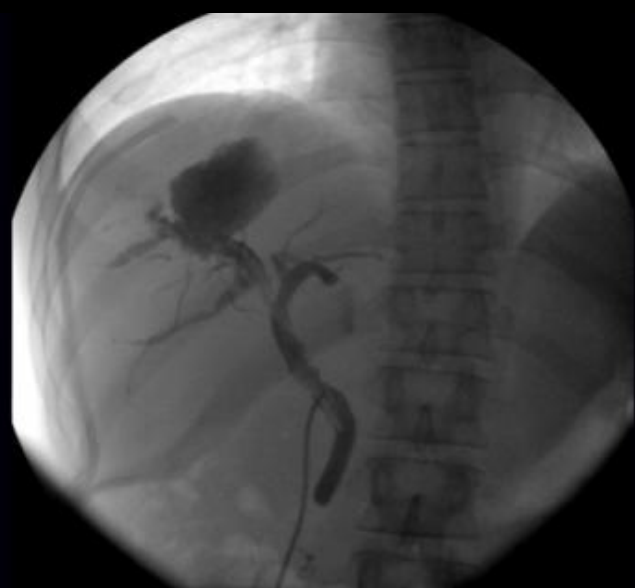Case 1

Map 3
150dB/C 3
Persist Med
2D OptHRes
Fr RateMax
BW 0 Pg 0
Col 0 Pg 0

Map 3
150dB/C 3
Persist Med
2D OptHRes
Fr RateMax
BW 0 Pg 0
Col 0 Pg 0



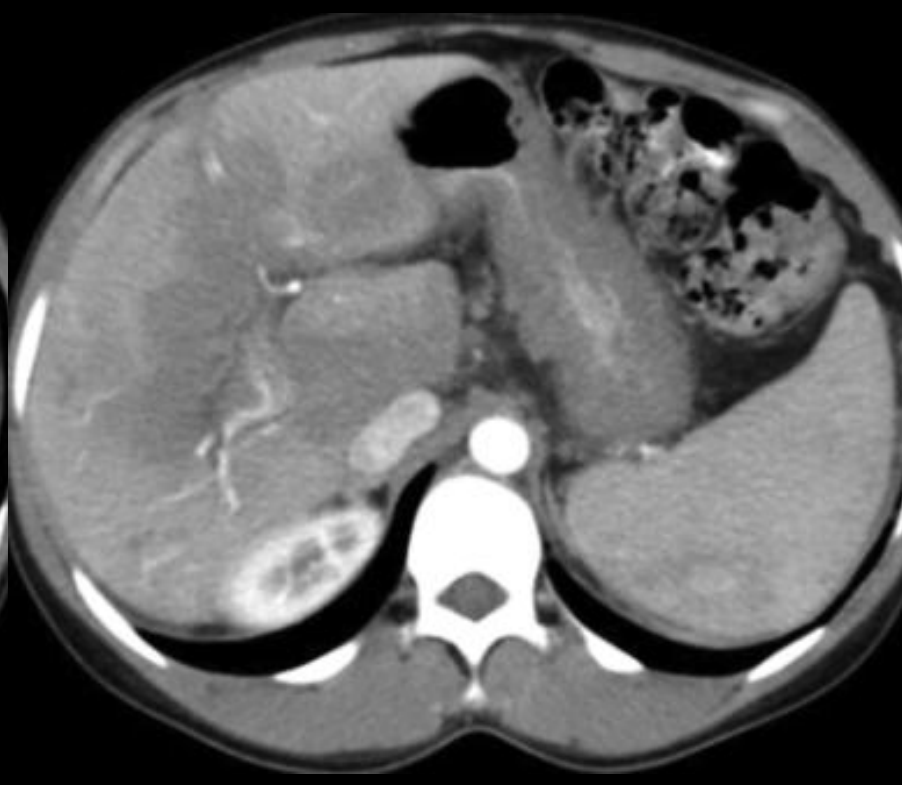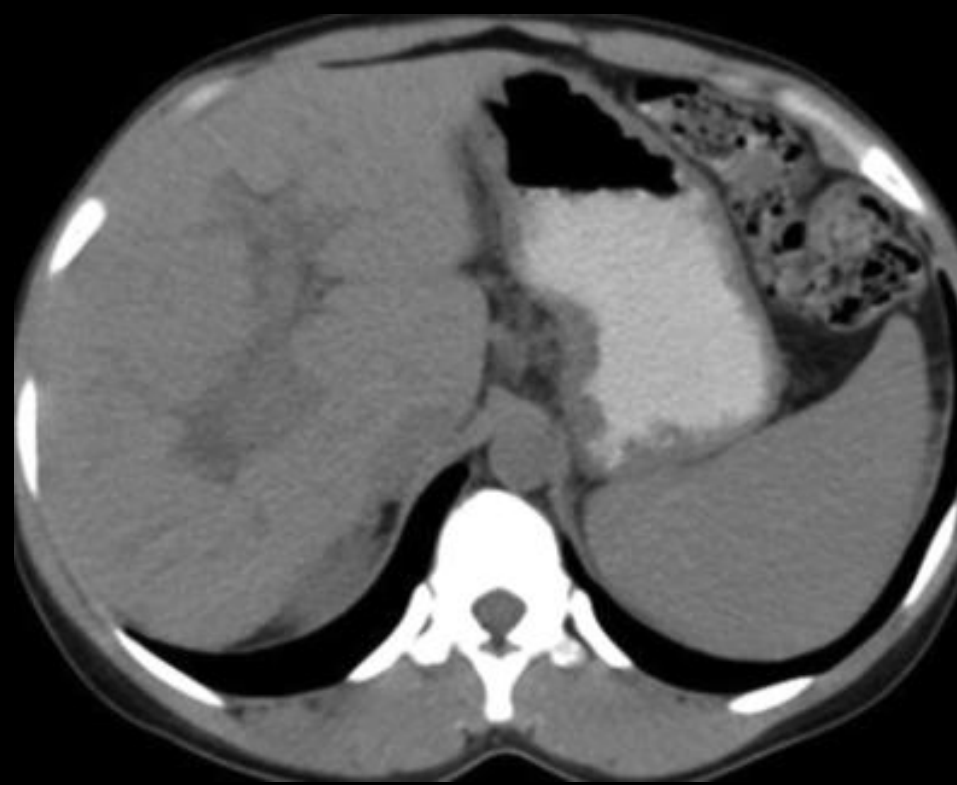


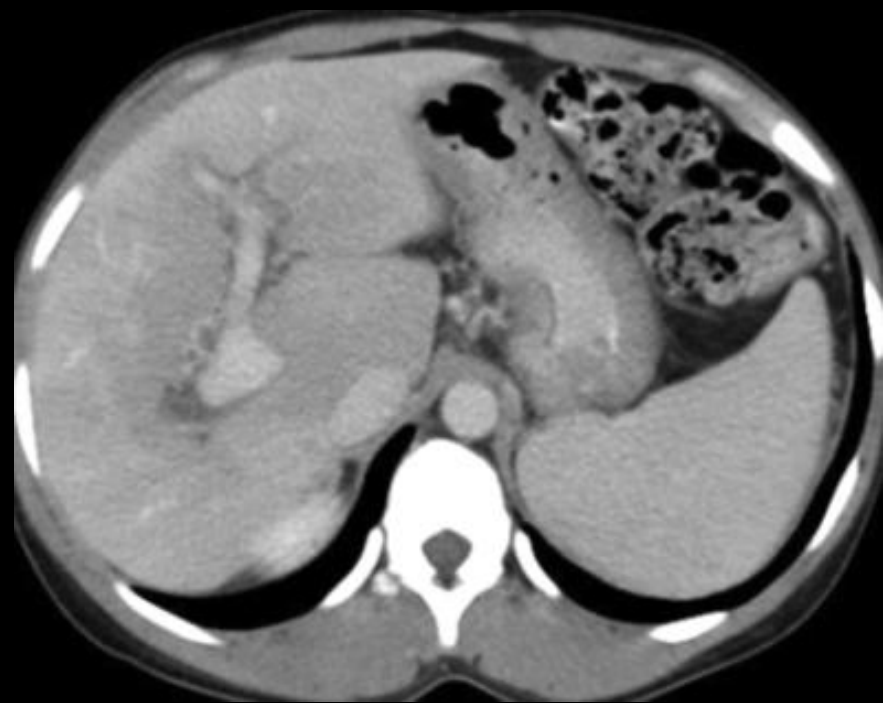
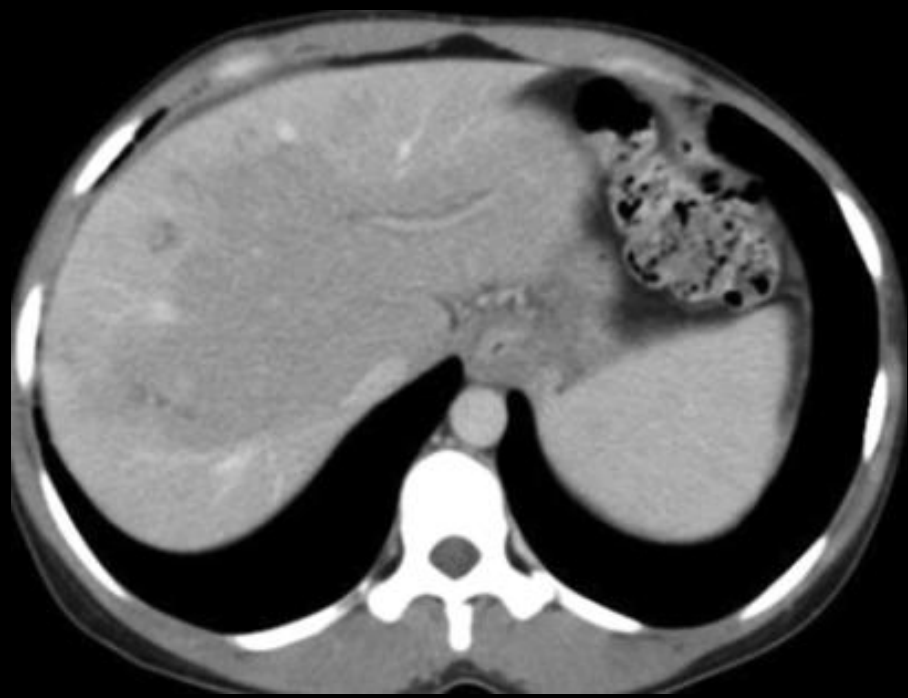


Hydatic cyst communicating with
bile ducts

Case 2

- 32-year-old female with progressive increase in abdominal girth
- Medical history included chronic HIV infection discovered in 2000, undergoing highly active antiretroviral therapy.
- Laboratory data revealed slight elevation of hepatic enzymes

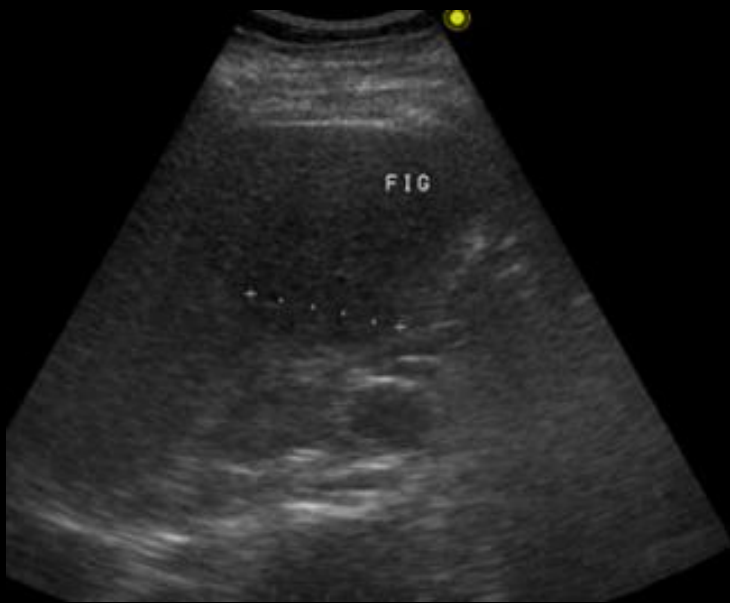




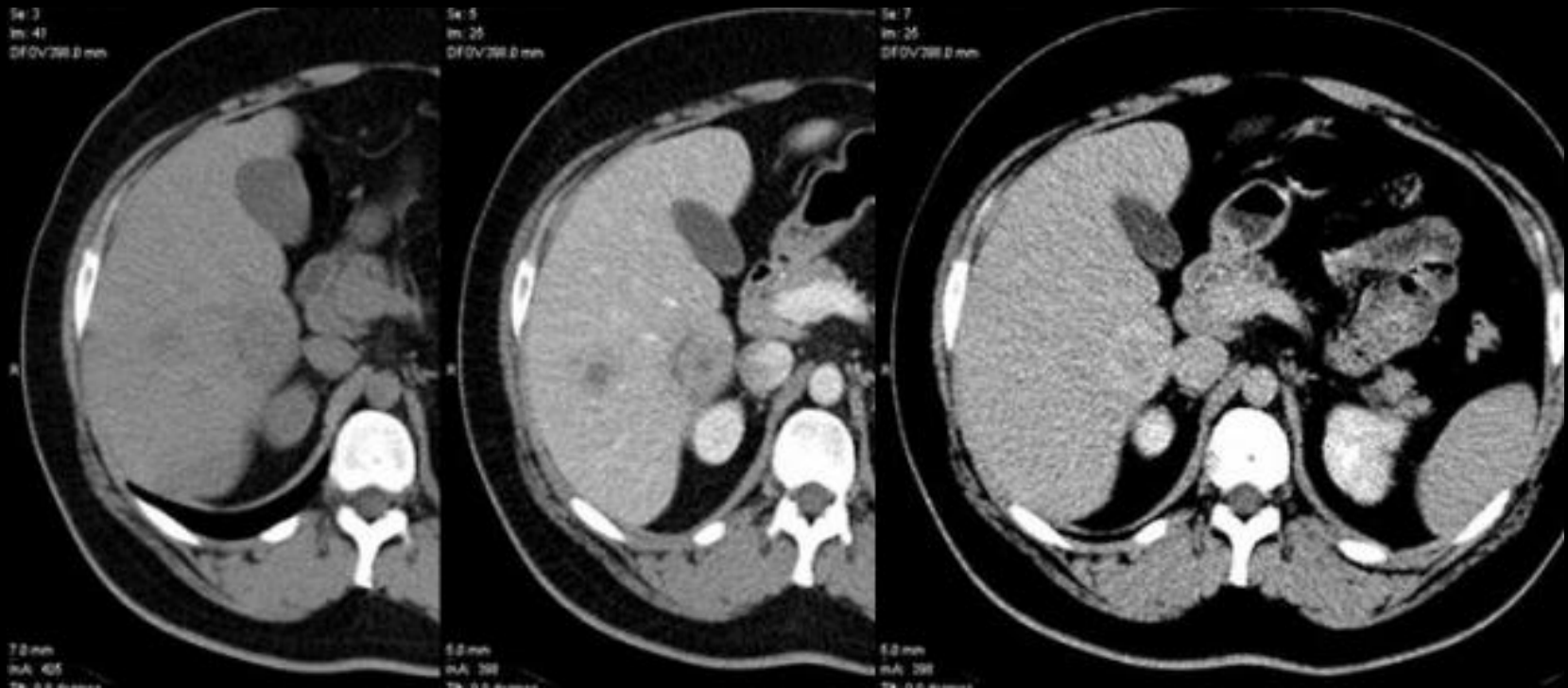
Obliterative portal venopathy

Case 3

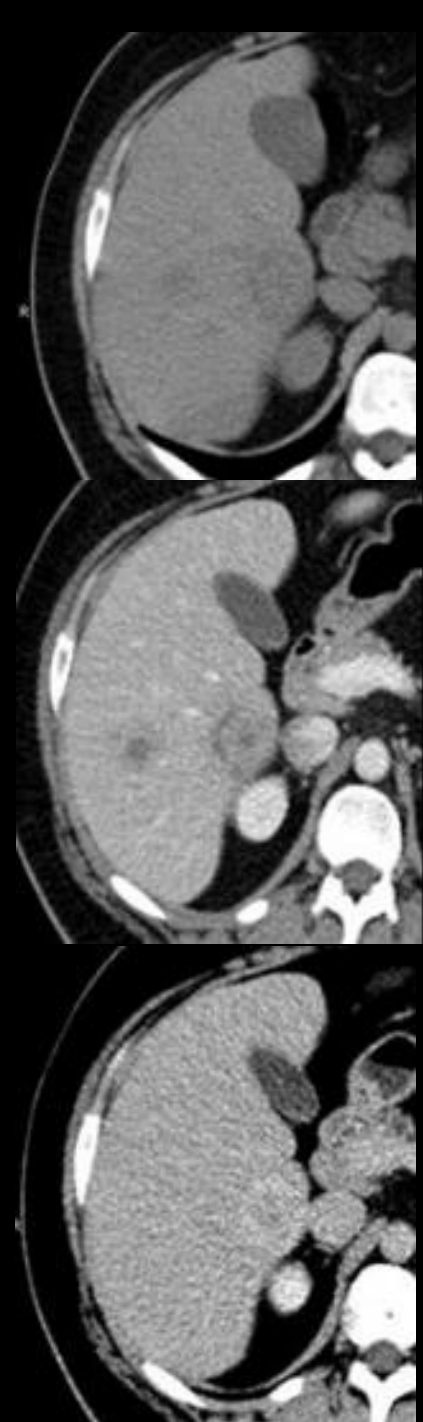- Male patient
- 28 years old
- Fever in last 5 days
- Leucocytosis



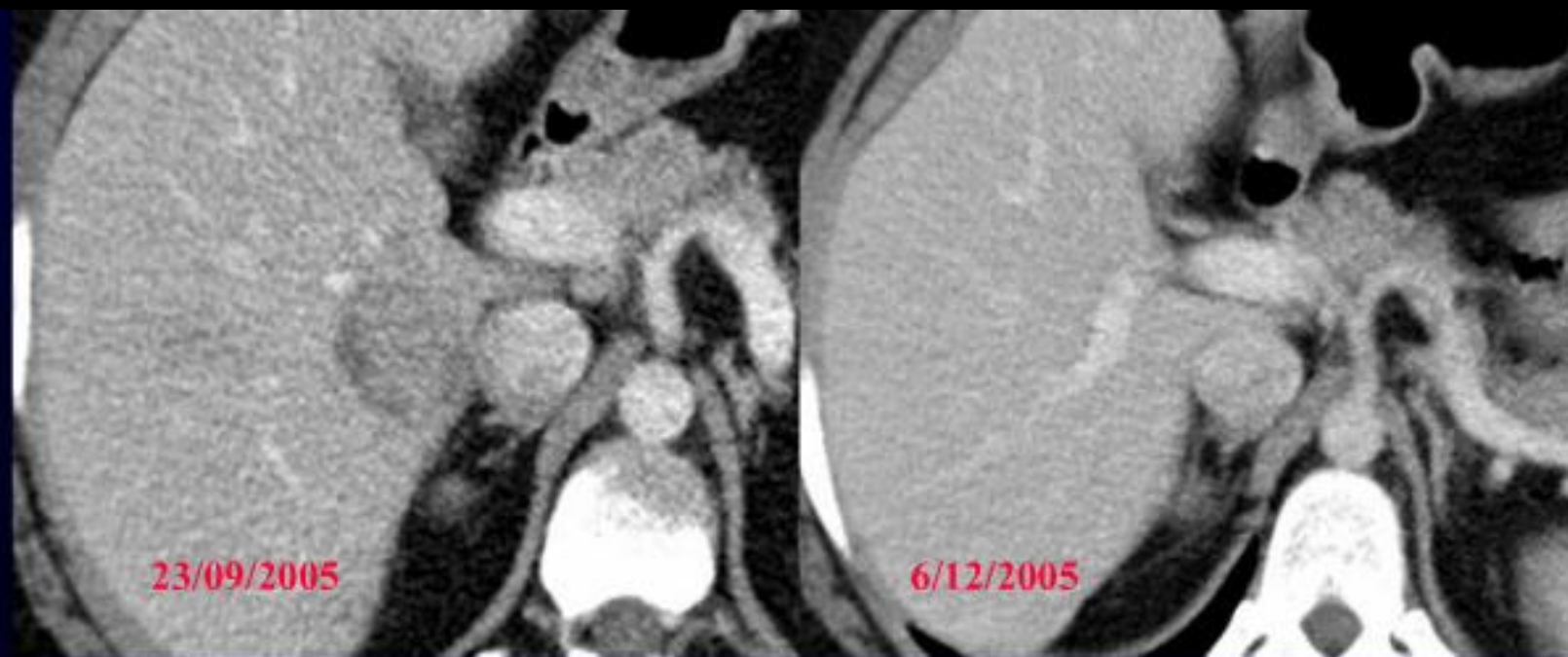- Ultrasound shows 2 lobulated hypoechogenic areas in right lobe of the liver



What is the best diagnosis?



- In this young patient with fever an infectious process was the first concern.
- There is no clear abscesses, since the lesions does no show liquid attenuation or ring enhancement.
- Instead we can see solid lesions, with contrast enhancement, hyper and isodense to liver in delayed phase.
- The bigger lesion with a central area hypodense in all phases, and a peripheral ring hypodense in portal phase and hyperdense in delayed phase

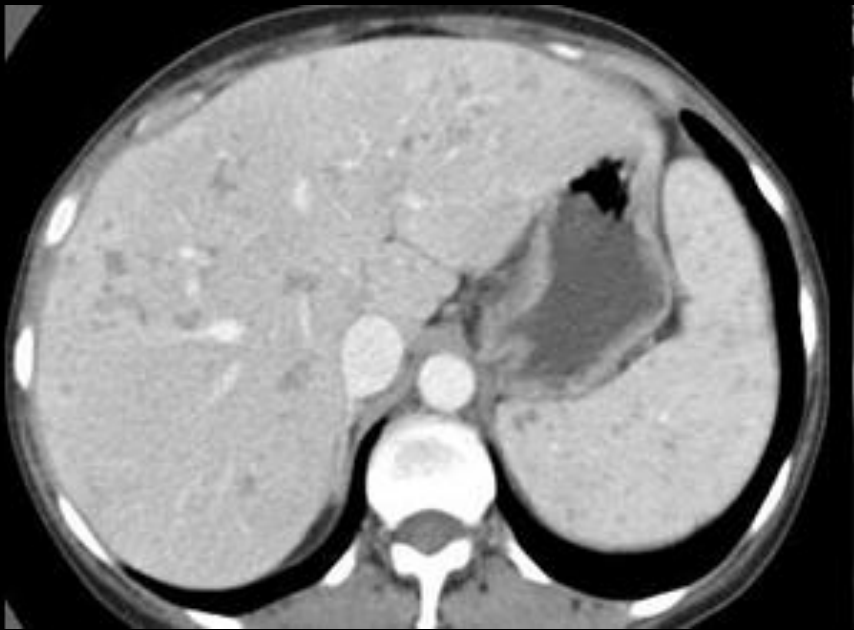

Complete resolution of lesions after antibiotics

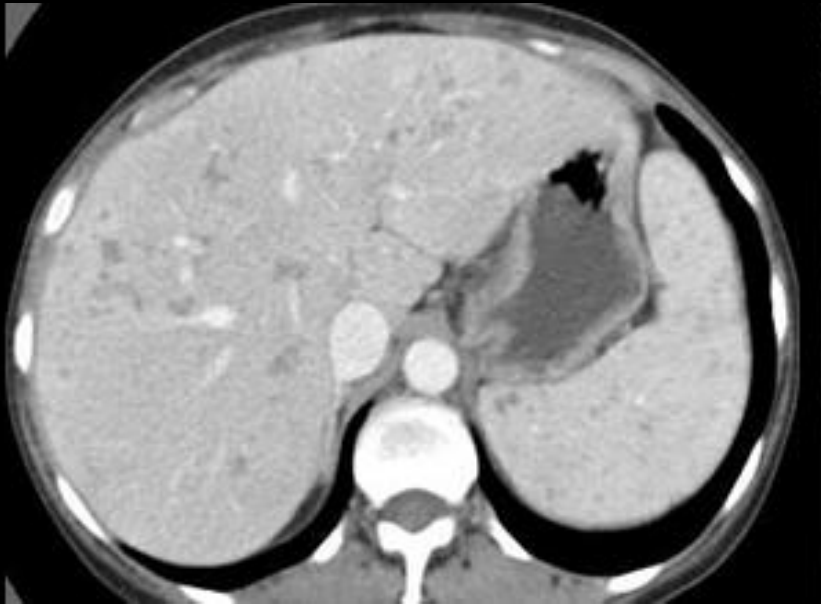Inflammatory pseudotumor

Case 4

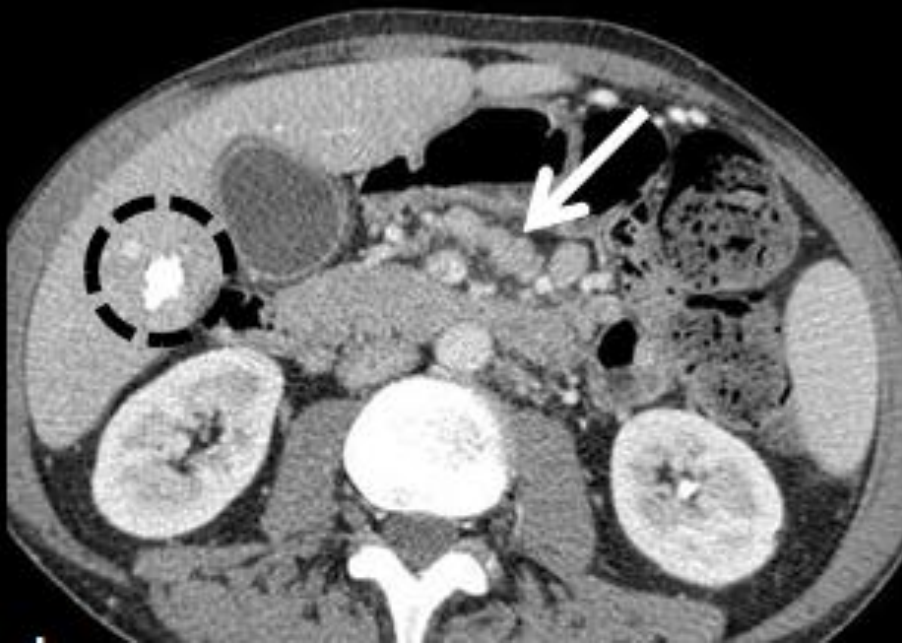- Male
- 40 years old
- HIV positive
- Low grade fever for months
- Haemoptyses
- Diffuse abdominal pain



- Which is the hepatic and splenic pattern present in this image?
- What are the differential diagnosis is this patient?



- Which is the hepatic and splenic pattern present in these images?
 - Miliary pattern
- What are the differential diagnosis is this patient?
 - Tuberculosis
 - Candidiasis
 - Sarcoidosis
 - Metastasis



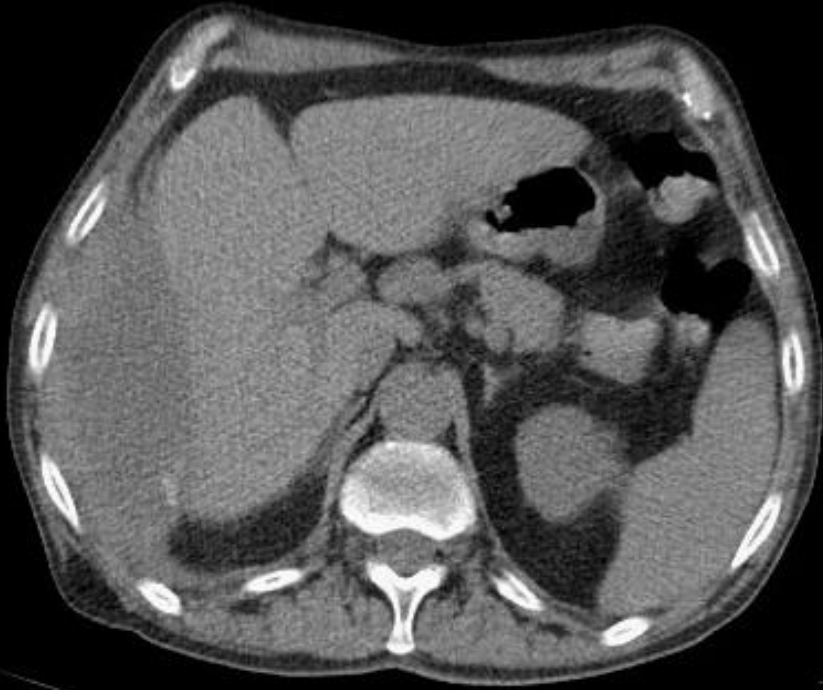- Does this image helps in the differential?

Miliary tuberculosis

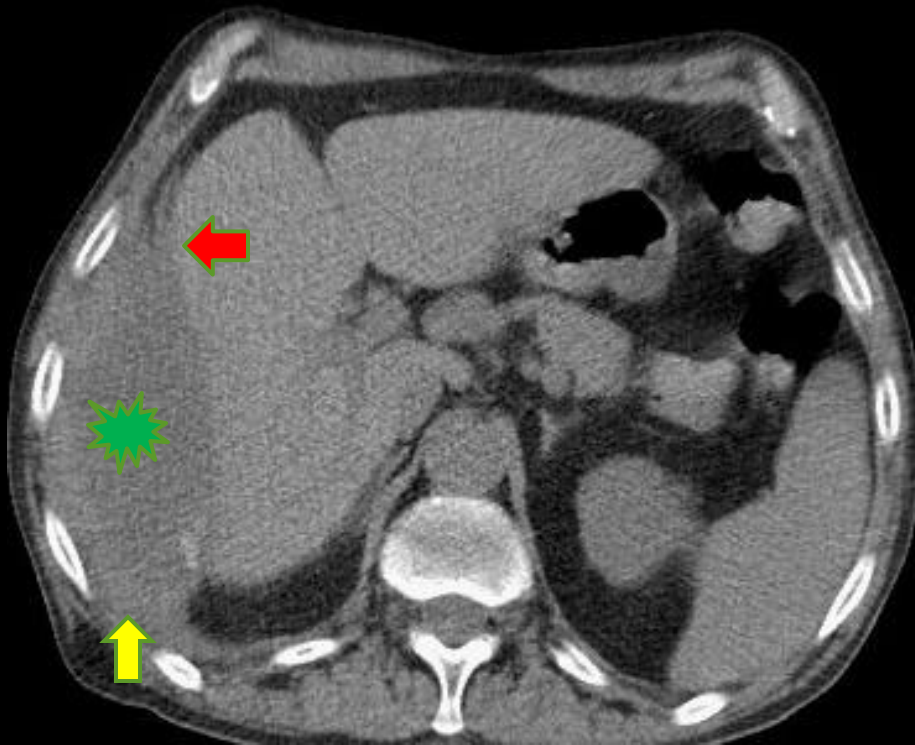
- Hepatic tuberculosis can have diverse presentations

Case 5

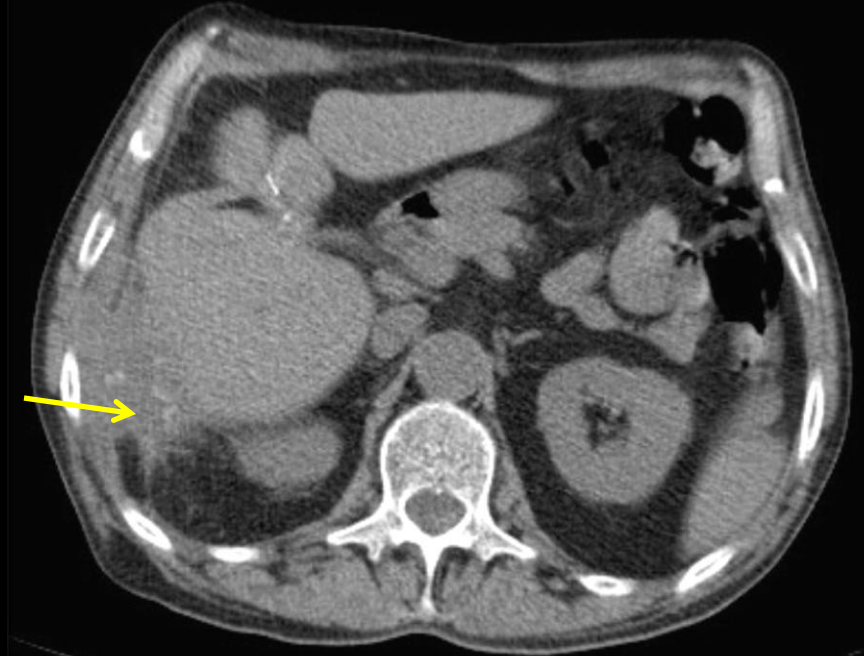
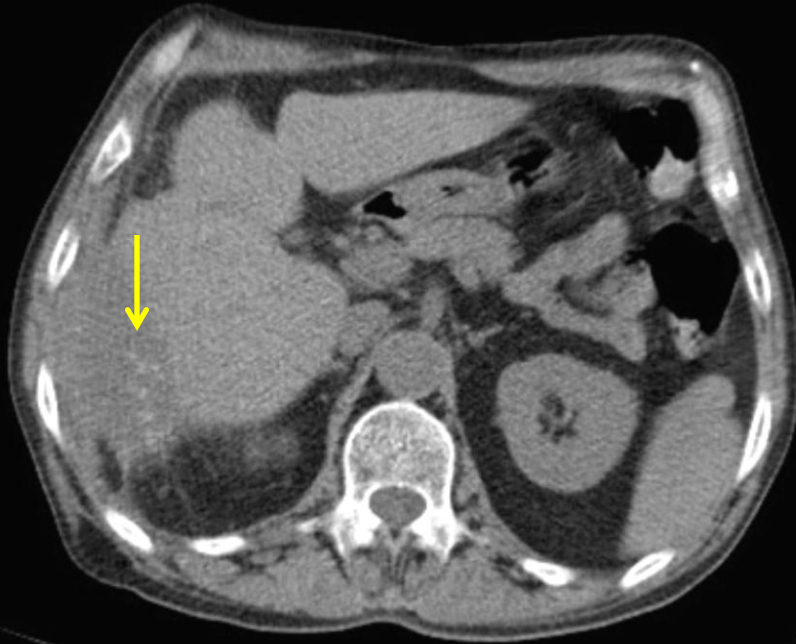
- Male patient
- Previous cholecystectomy
- Since surgery had fever and abdominal pain
- Abdominal abcess diagnosed by ultrasound
- Transferred to our hospital for drainage



- Is this collection intra-hepatic, sub-capsular or peritoneal?
- Where is the relevant clue to the cause of this collection?



- **Yellow arrow** points to peritoneal thickening in reaction to the collection
- **Red arrow** demonstrate a obtuse angle with liver parenchyma
- Green star shows the equator of the collection outside the liver



The yellow arrow points to small stones inside the collection, that infected the peritoneal space after surgery. Without remotion of these stones, drainage will not be effective

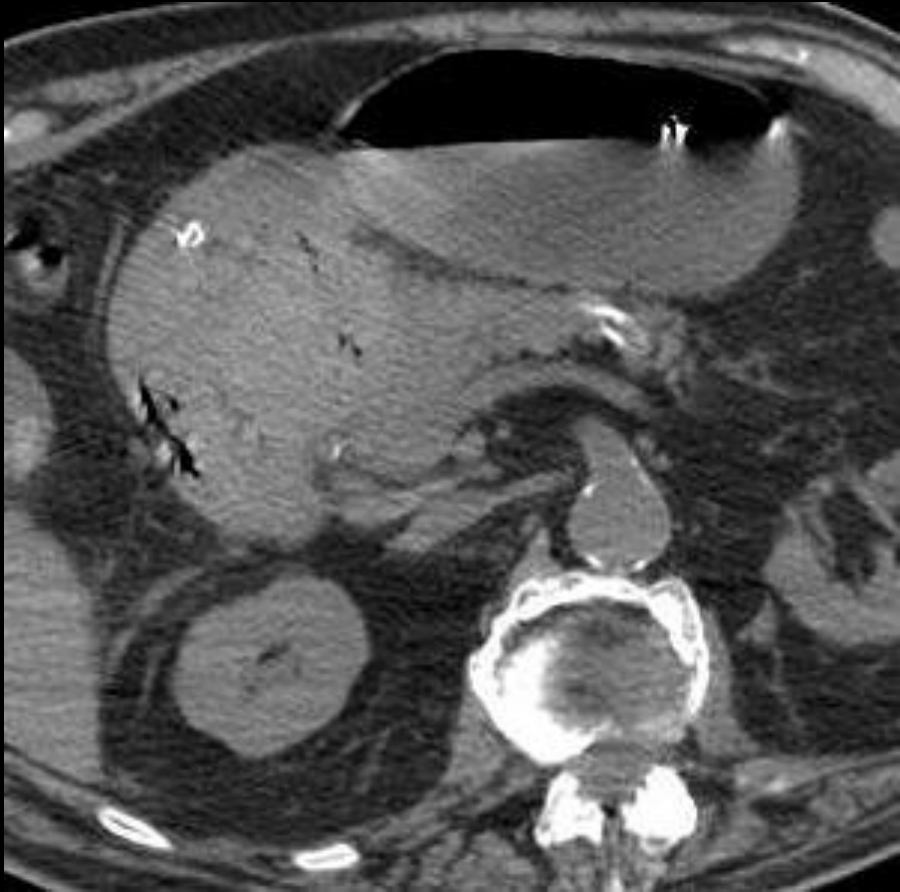
Dropped gallstones

- Laparoscopy has become the procedure of choice for routine cholecystectomy.
- If a spilled stone is retained in the abdominal cavity, recurrent intra-abdominal abscess may occur has a delayed complication.
- This diagnosis is important because simple abscess drainage and antibiotics are typically not enough to treat such cases.

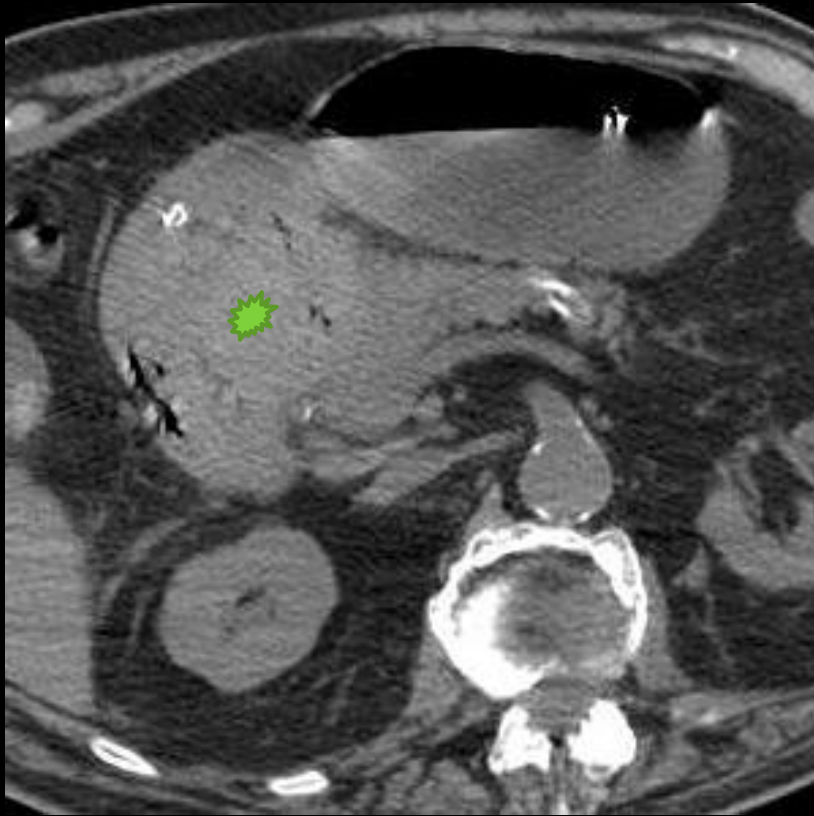GASTRO-DUODENAL REGION

Case 6

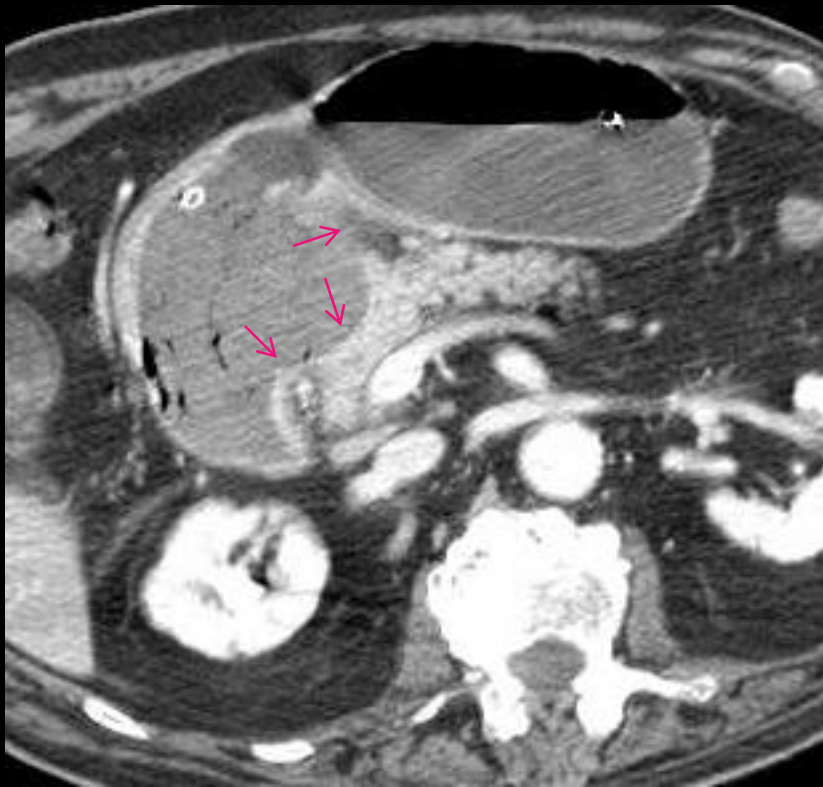
- Man, 89 The stasis with vomiting and abdominal distension. Clinical suspicion of acute diverticulitis.



- What was probably missing in the clinical information?
- Should the radiologist contact the gastroenterologist by phone?



- There is a hyperdense clot bulging from gastric lesser curvature
- The patient said to us that he had one episode of haematemesis two days earlier
- Probably no contact is necessary, because patient was stable



- In this image the line of enhancement that marks the gastric wall is absent
- At first we thought that a complete perforation was not possible, since there is no free abdominal air or abdominal fluid

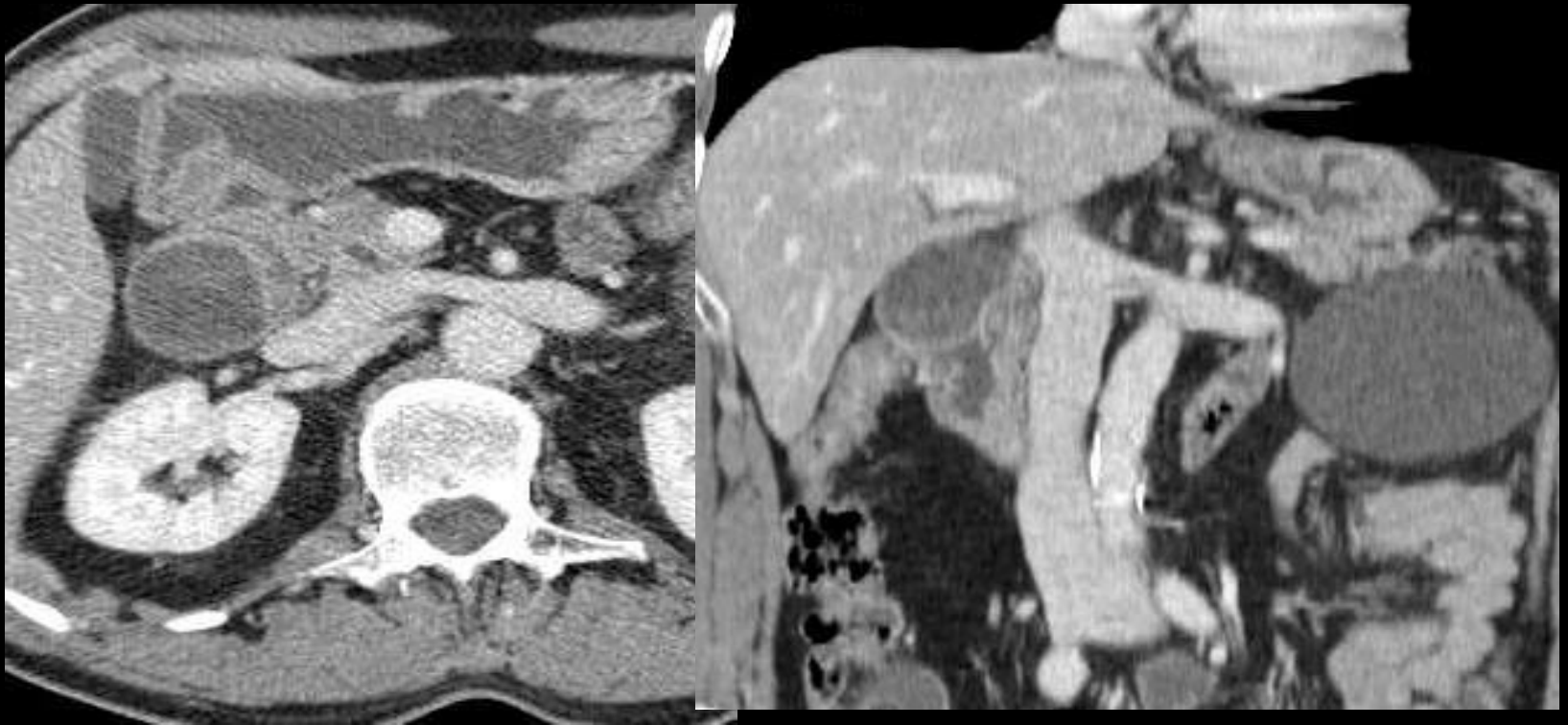
Sealed perforated gastric ulcer

- Gastroenterologist reported to us an enormous ulcer sealed by a clot
- Surgeons refused operation since the patient had several co-morbidities
- Unfortunately the patient died 5 days later

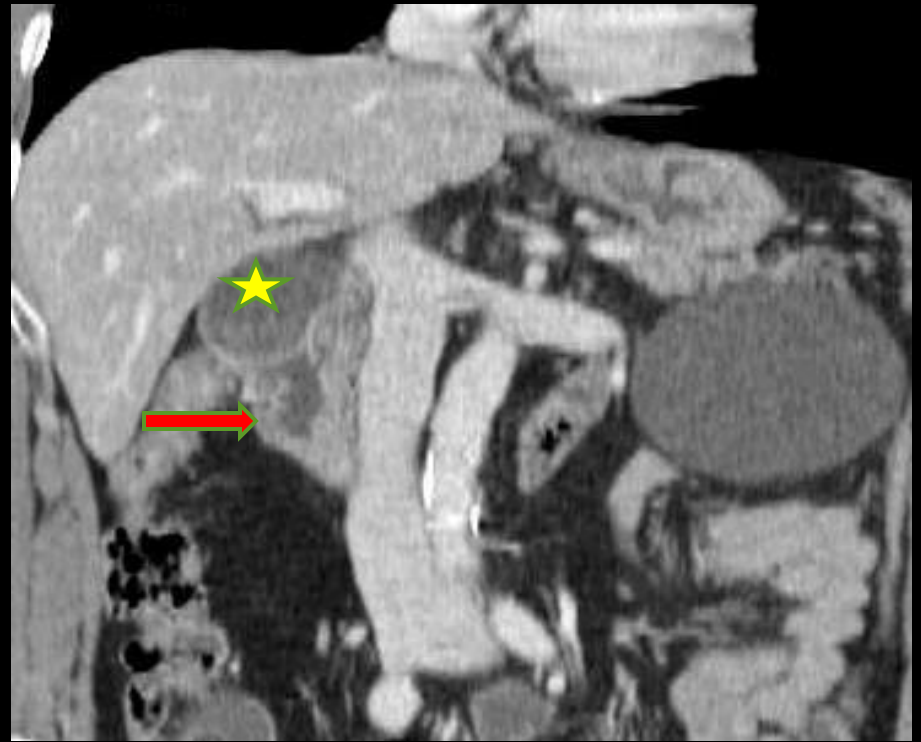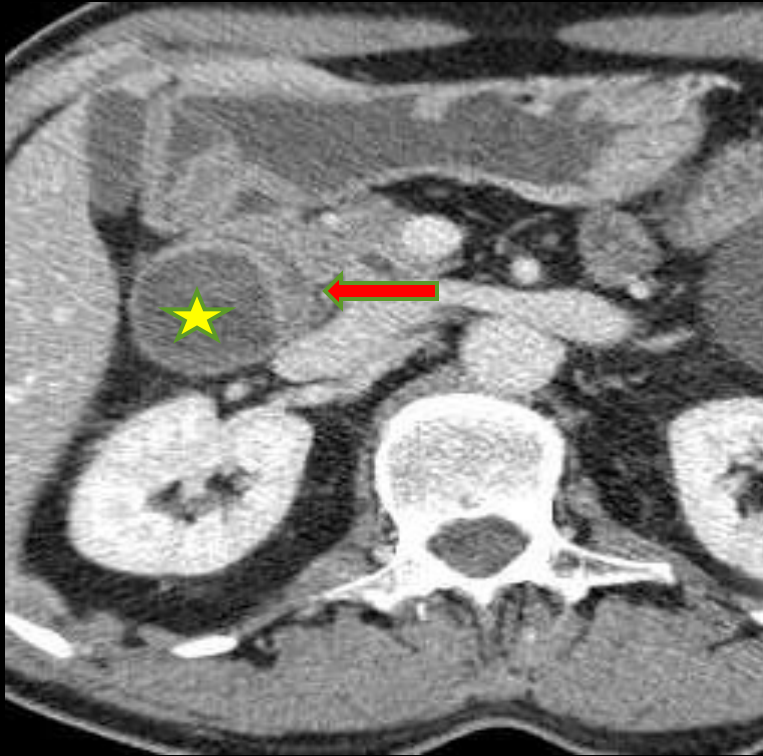
Case 7

- Man, 61, with upper abdominal pain, vomiting and regurgitation of food. Clinical suspicion of high intestinal obstruction.
- The endoscopic study showed stenosis of the duodenal lumen, probably due to extrinsic compression of the duodenal arch.

What is causing obstruction?



Where is the duodenal lumen?



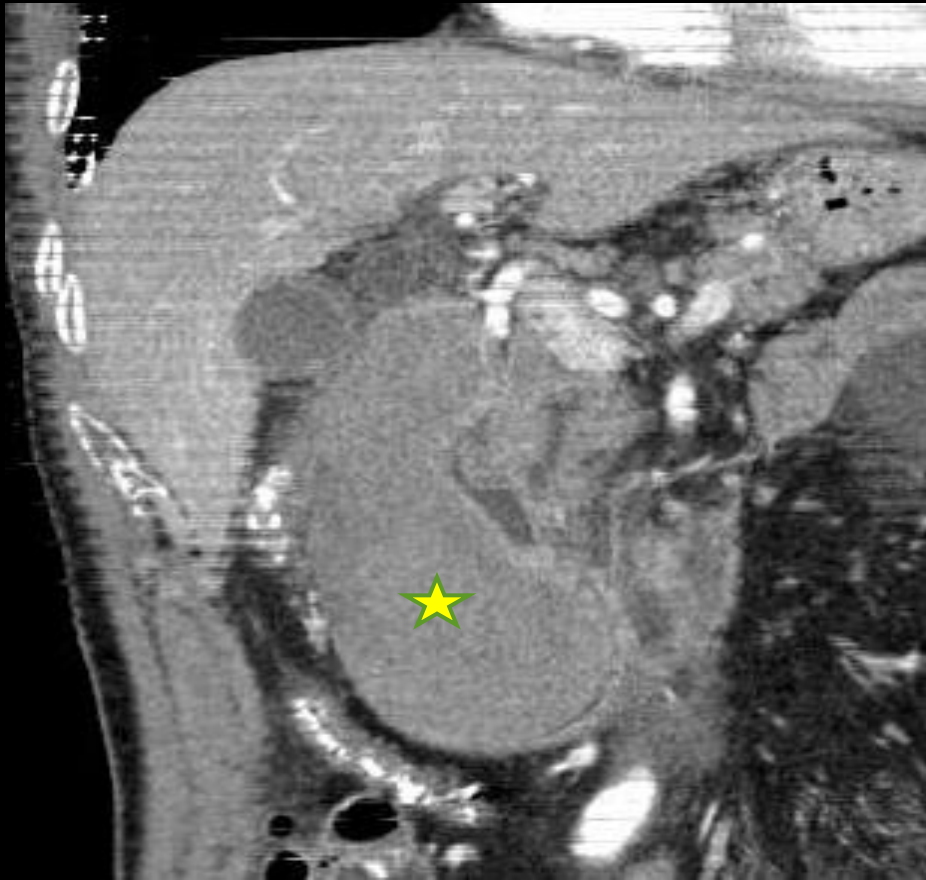
Yellow star marks the equator of the cystic structure that is compressing duodenal wall. The cyst has no calcifications, but have an enhancing regular wall

Red arrow points to duodenal mucosa, and duodenal lumen. Mucosal folds permits identification of bowel wall

To days later

Patient returns to urgency with:

- Excruciating abdominal pain
- Syncope



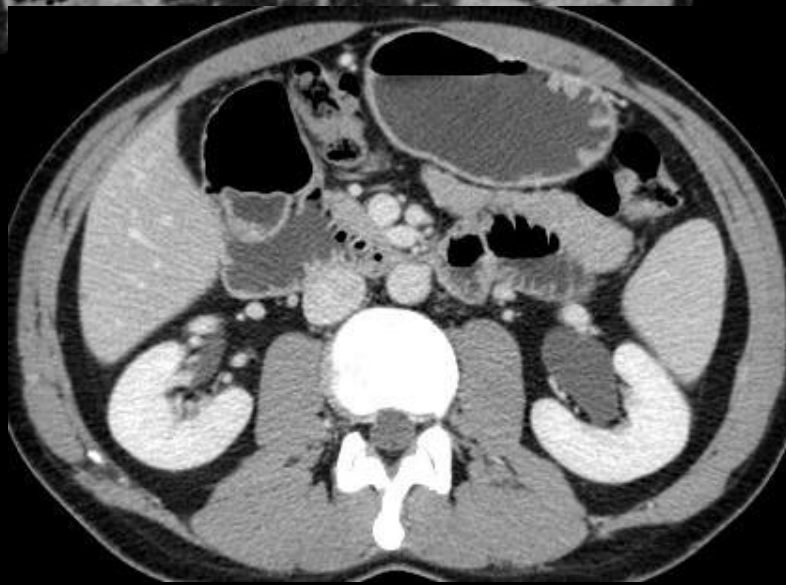
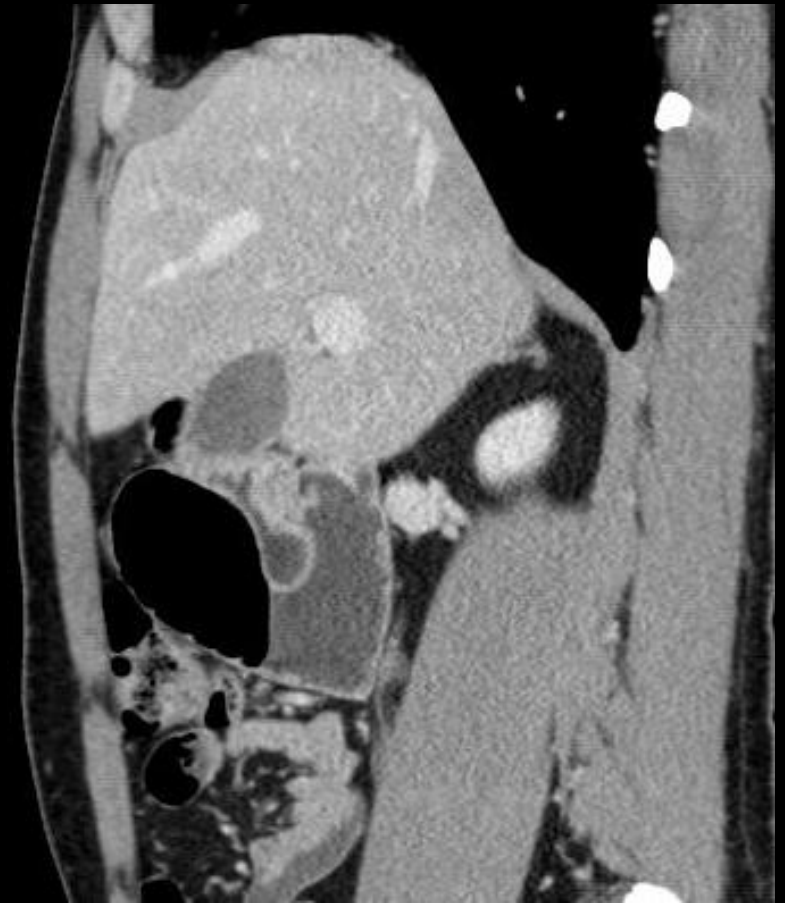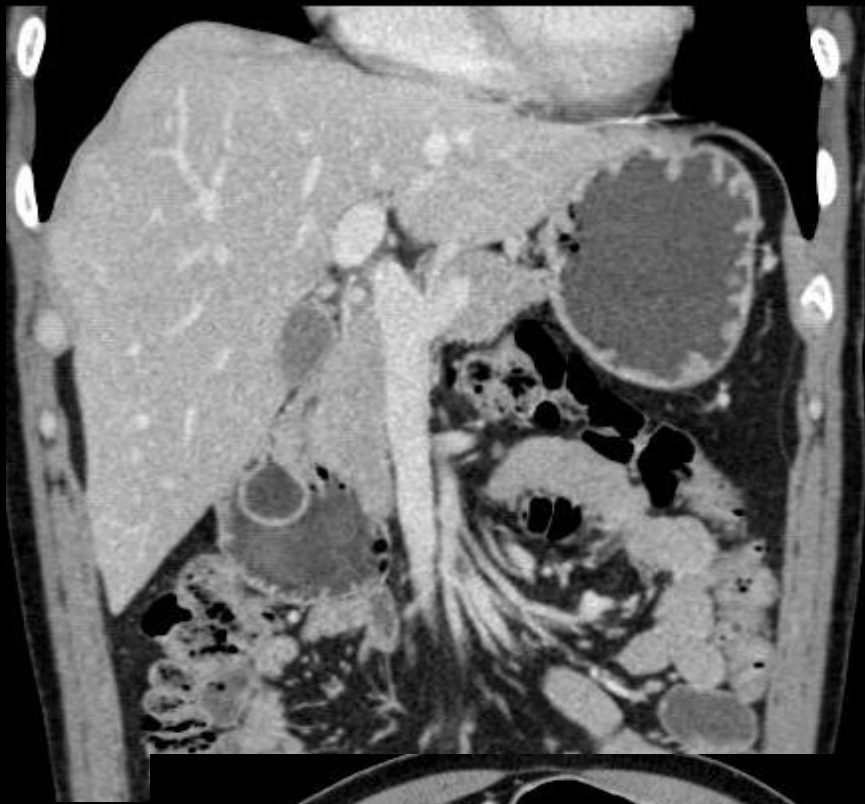
- Coronal reformats of CT showed enlarged diverticulum, with hyperdense content, but no active bleeding

Duodenal diverticulum with internal bleeding

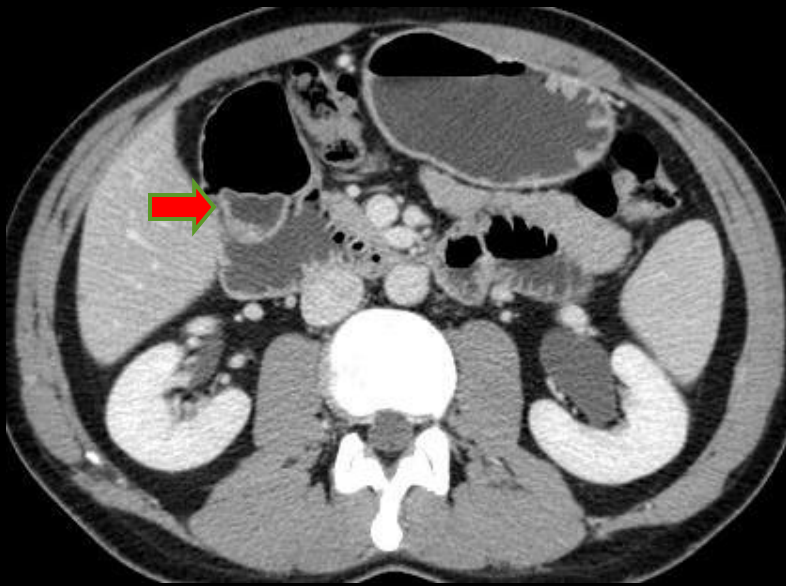
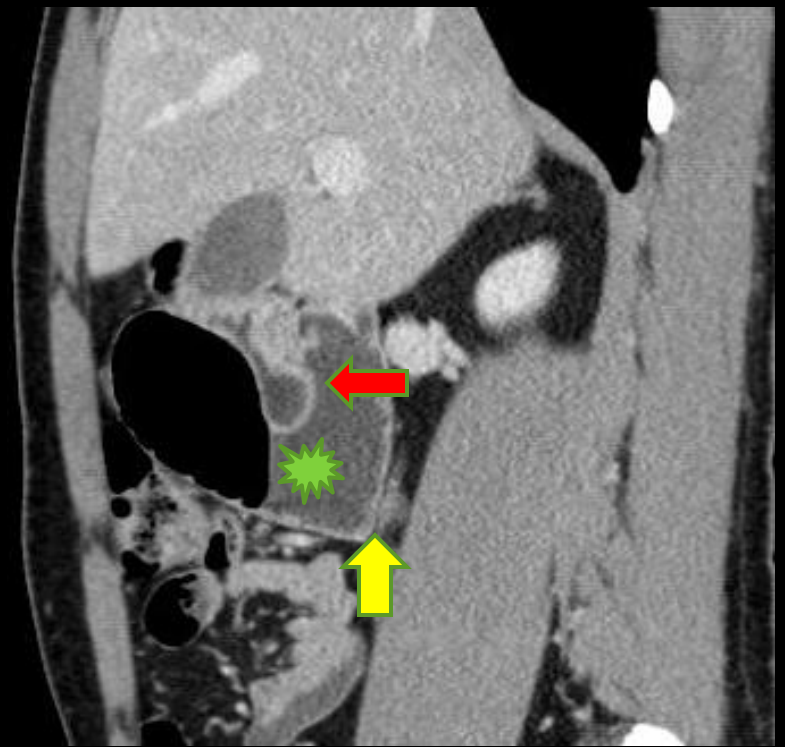
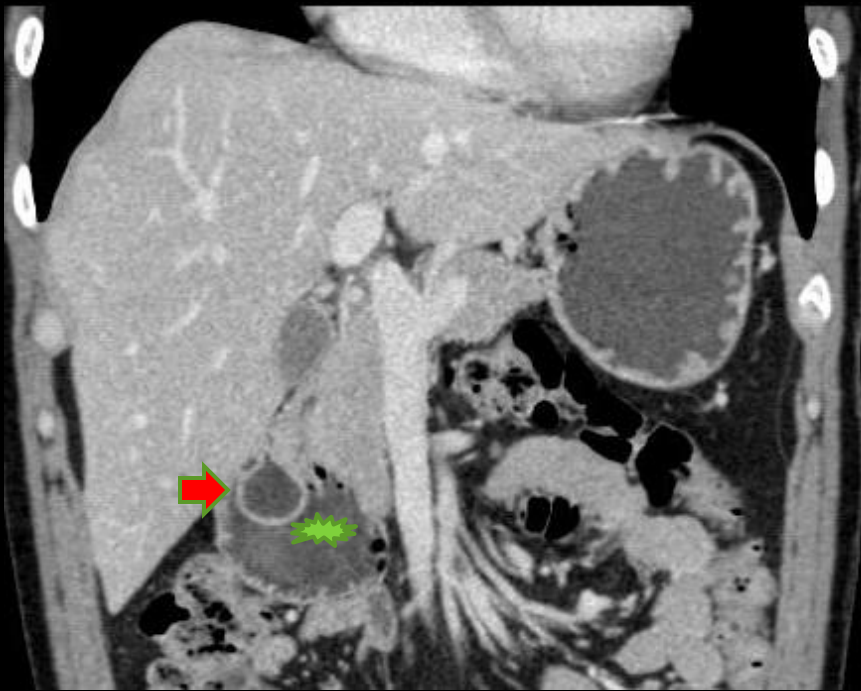- Medial location in 70% of cases
- Usually asymptomatic
- Complications include: Diverticulitis, hemorrhage, obstruction, perforation and pancreaticobiliary disease
- Differential diagnosis: Pseudocyst, pancreatic cystic tumor and perforated duodenal ulcer.
- Communication with duodenal lumen is fundamental for diagnosis

Case 8

- 29-year-old male
- Prolonged history of progressively worsening upper abdominal pain, postprandial vomiting, and weight loss.
- Past medical history, physical examination and laboratory studies were unremarkable.



Where are the relevant findings in these images?

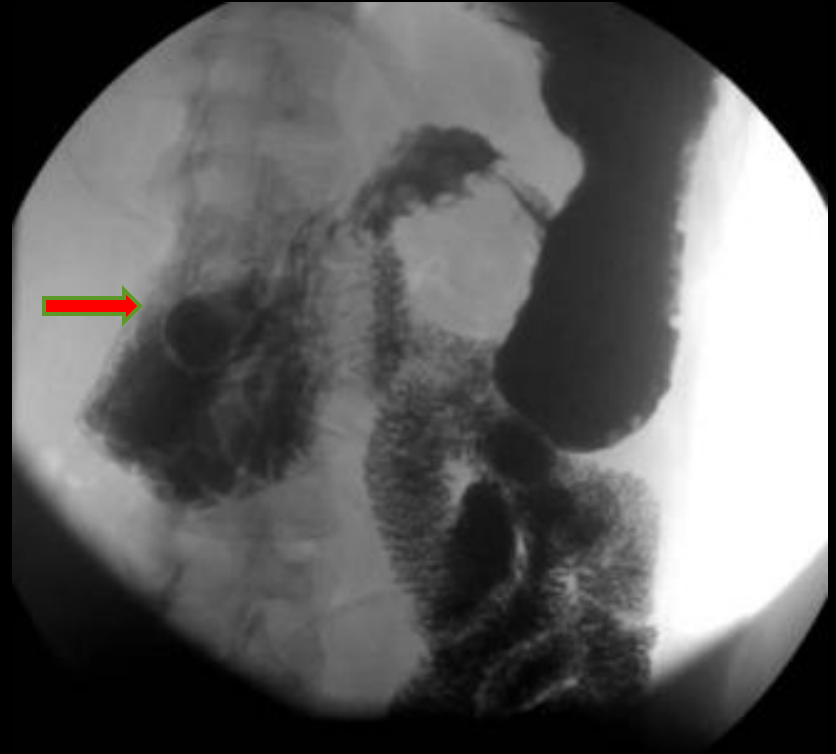
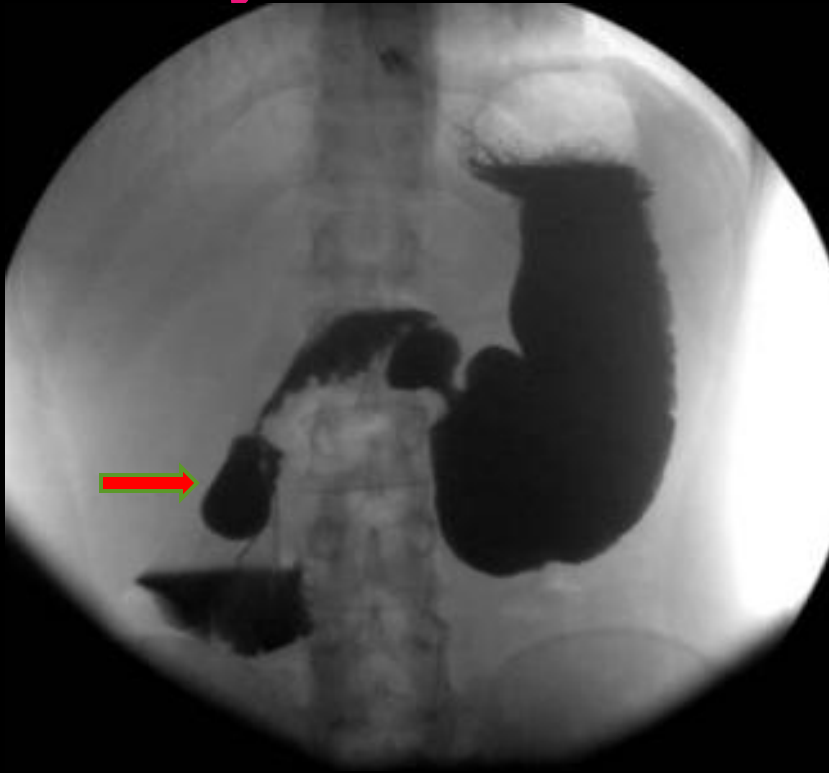

Green star- Dilatation of the lower descending and proximal third part of the duodenal arc

Red arrow- Ring-like soft-tissue density, with liquid heterogeneous content, within the lumen of the duodenum

Yellow arrow- No discernible obstructive cause

Later gastro-duodenal barium study



An upper GI series showed a barium-filled sac structure (red arrow) surrounded by a radiolucent halo in the second portion of the duodenum, and some delayed passage of contrast into jejunum, but without any organic identifiable lesion

Intraluminal duodenal diverticulum

- Treatment:
- The treatment is surgical or endoscopic excision, carefully avoiding injury to the ampulla of Vater .

- Teaching points:
- 1. IDD is a rare developmental anomaly of the duodenum.
- 2. The duodenal “wind sock sign” is a pathognomonic finding of this entity.
- 3. MDCT with multiplanar reformations are helpful in characterization and can further disclose associated congenital malformations.
- 4. There is a 40% incidence of coexisting congenital abnormalities, which include Ladd band, annular pancreas, choledochoceles, portal vein anomalies. Ladd bands can cause obstructive signs and symptoms like in the present case.

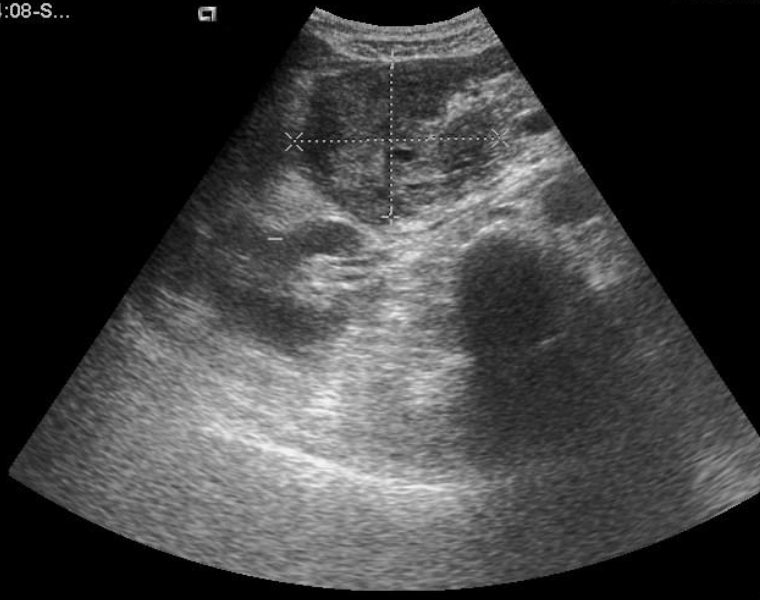Case 9

- Male patient
- Alcohol abuse
- Intense epigastric pain
- Elevated amylase

06.11.02-09:04:08-S...
02-11-2006
9:06:38

CH4-1
ABDOMINAL
19fps
MI:0.8

GEN/4.0 MHz
8dB/DR65
MapG/VEOff
RS2/SC1



✚D=55.3 mm

✚D=73.1 mm

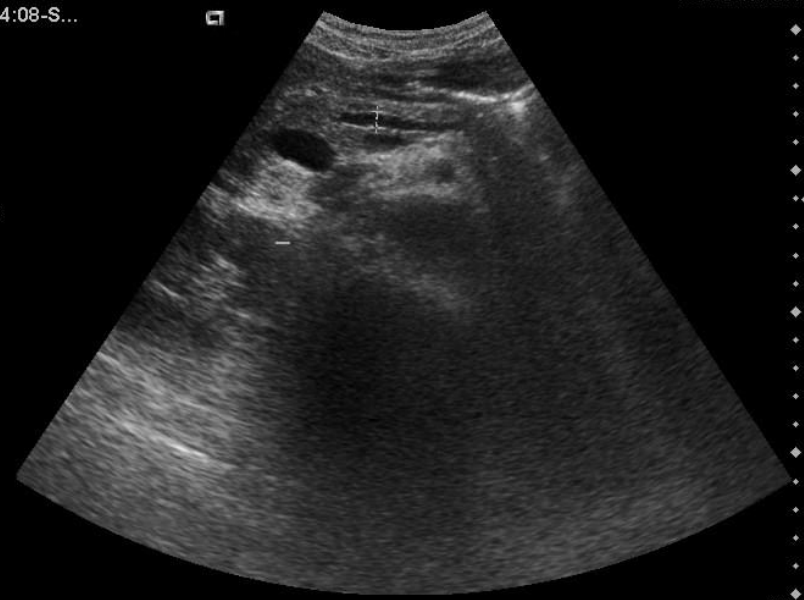Fr7
SIEMI

H.U.COIMI

06.11.02-09:04:08-S...
02-11-2006
9:07:48

CH4-1
ABDOMINAL
19fps
MI:0.8

GEN/4.0 MHz
3dB/DR65
MapG/VEOff
RS2/SC1



✚D=5.6 mm

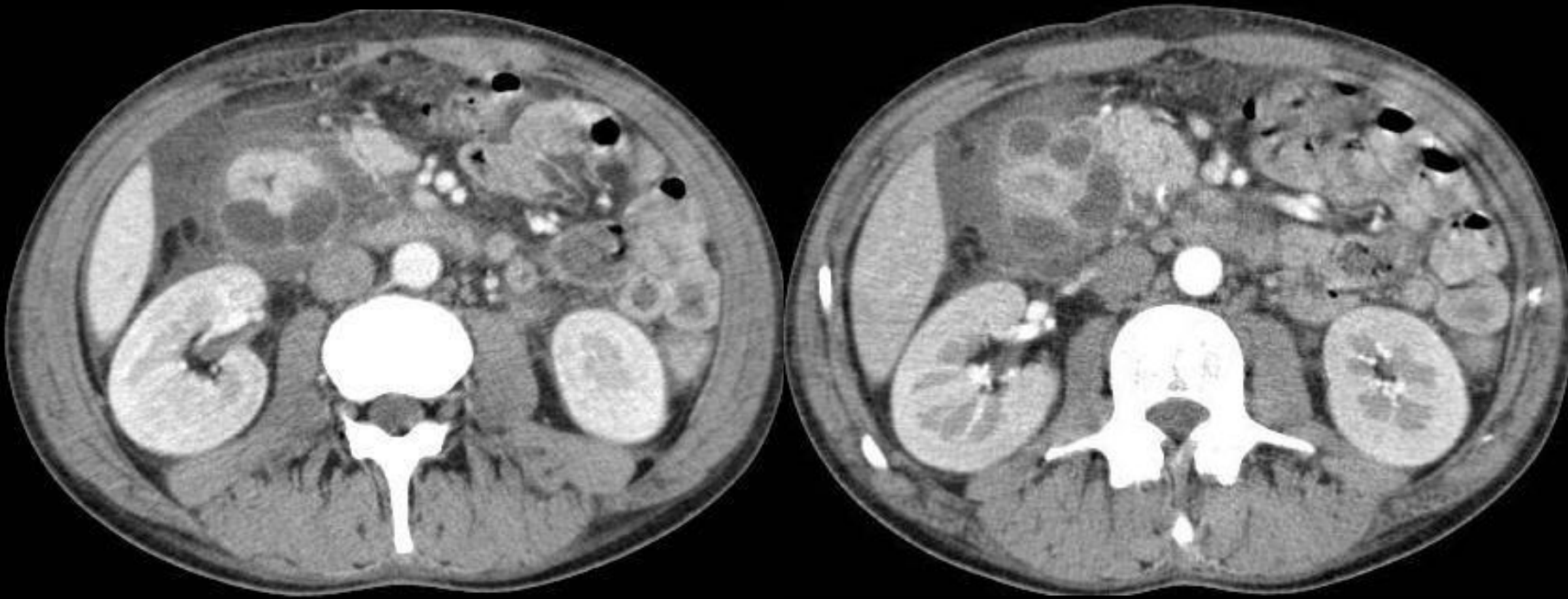
Fr257
SIEMENS

H.U.COIMBRA

20cm
19fps

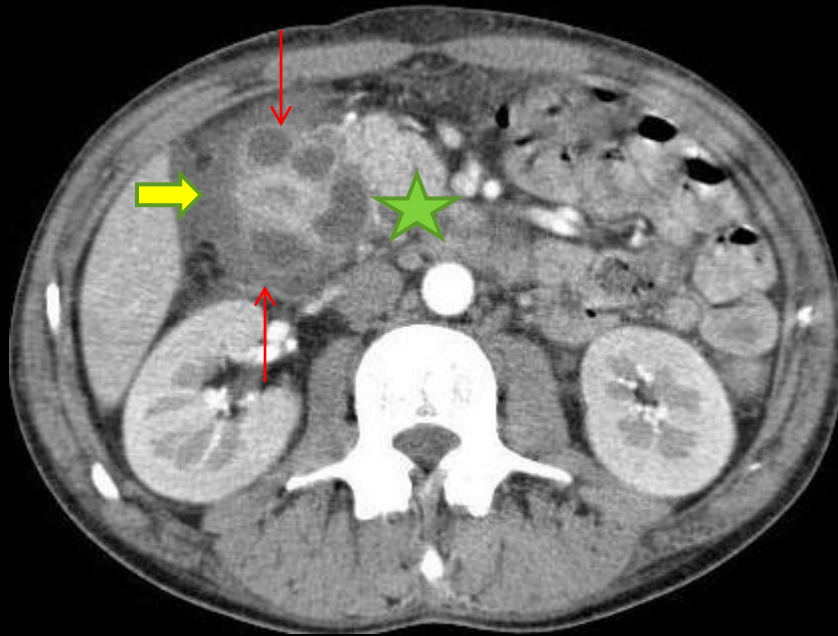
- What are the structures highlighted by markers on the abdominal ultrasound ?

- Probably correspond to duodenum and peri-duodenal cystic structures with internal echos.



- It seemed a tumor, on ultrasound.
 - Differential diagnosis?

- On CT there is no doubt that we can see peri-duodenal cystic structures (red arrow), thickened duodenal wall, and localizes ascites (yellow arrow)
- Pancreatic parenchyma has normal size and enhancement (green star)



- If we recognize the arrangement of the cysts, a pancreatic cystic tumor should be excluded.
- Also a large necrotic neuroendocrine tumor could be excluded since the walls thick and irregular
- Duodenal duplication cyst is not multilocular
- If we know the entity called groove pancreatitis the diagnosis should be straightforward

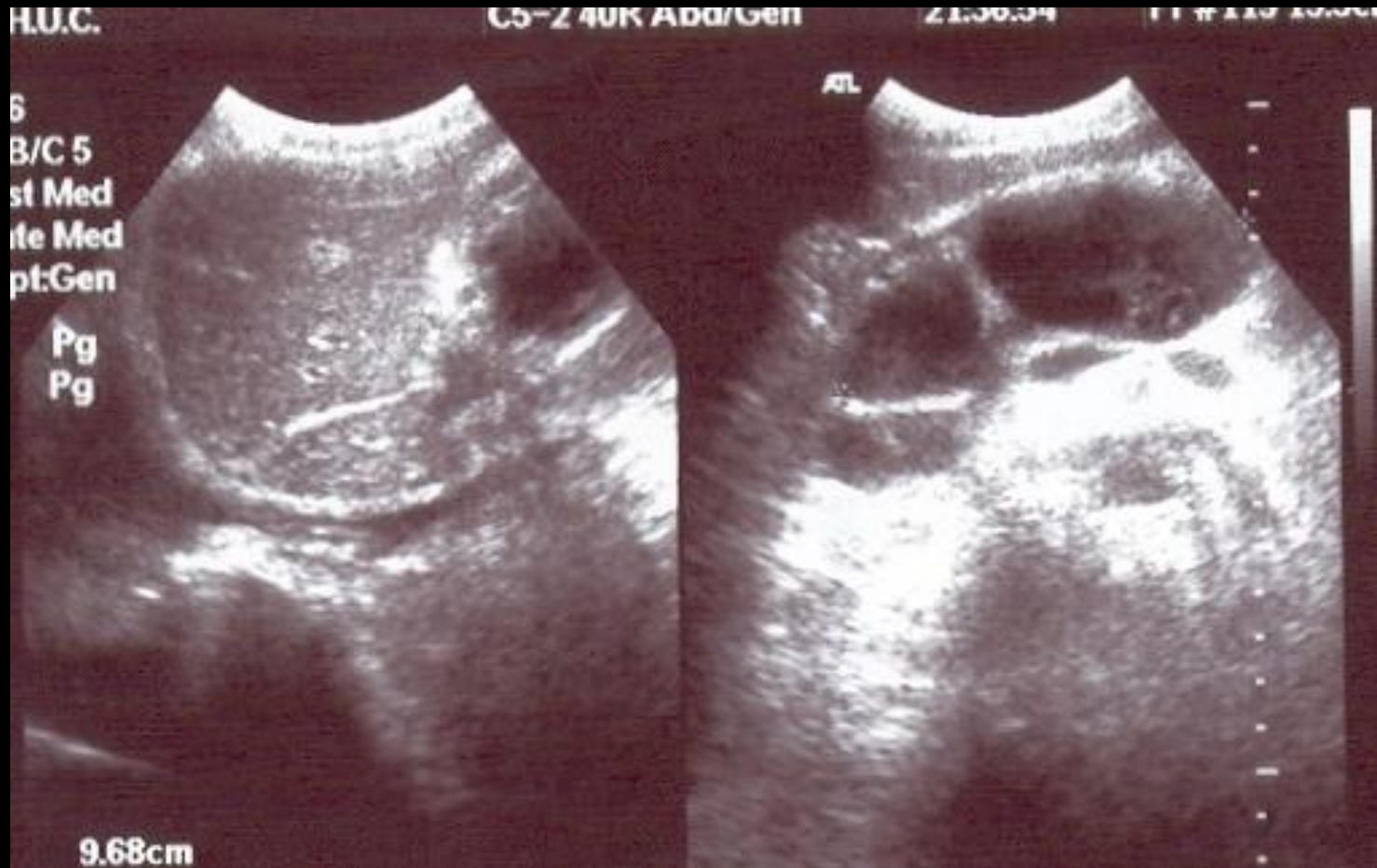Groove pancreatitis

- Is a subtype of chronic pancreatitis
- Alcohol is an important risk factor
- Inflammatory process is typically restricted to the groove between pancreas and duodenal sweep
- In some cases common bile duct and wirsung can be involved

PANCREAS

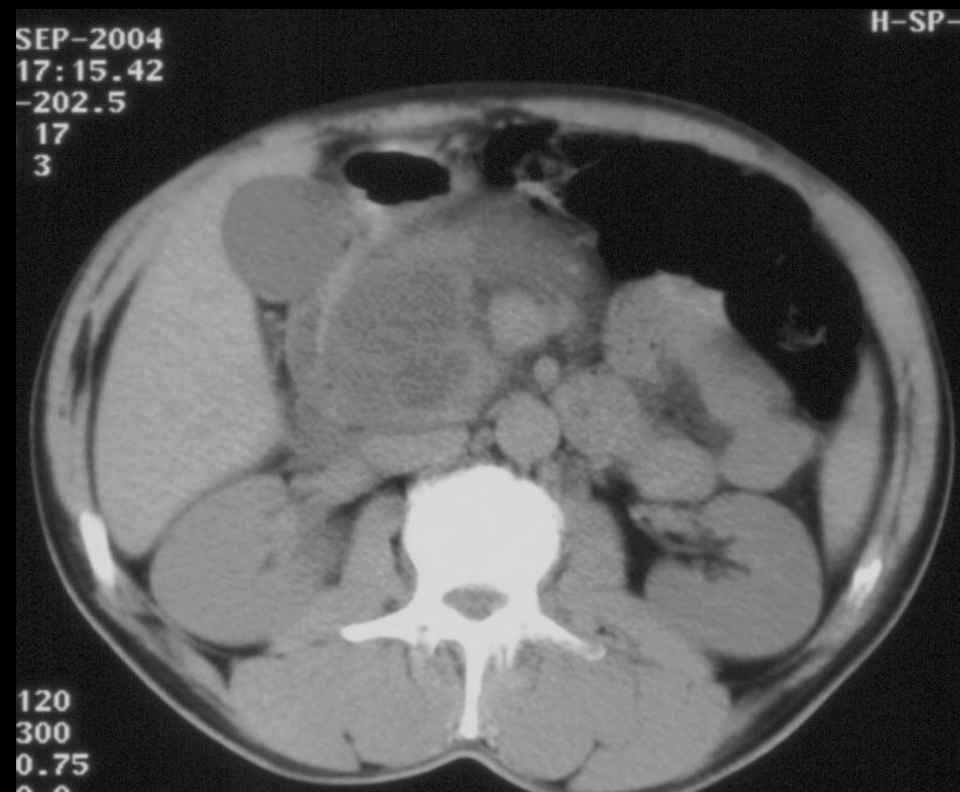
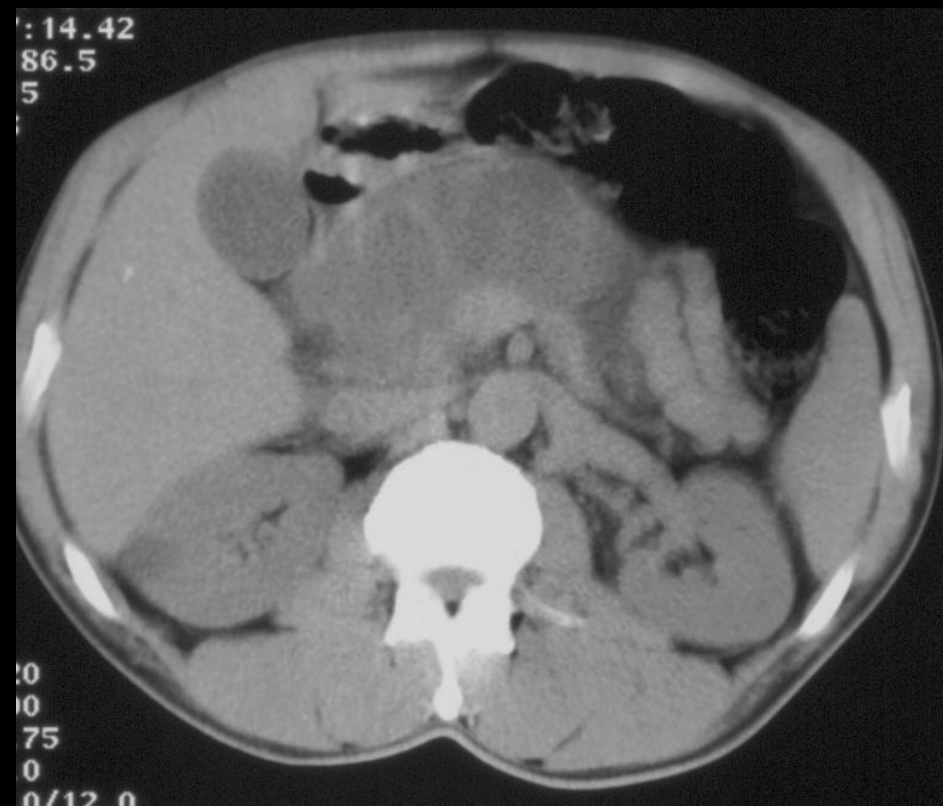
Case 10

- Male patient
- 68 years old
- Came to the urgencies with complaints of abdominal epigastric pain for 20 days
- Surgeon asked for an abdominal ultrasound

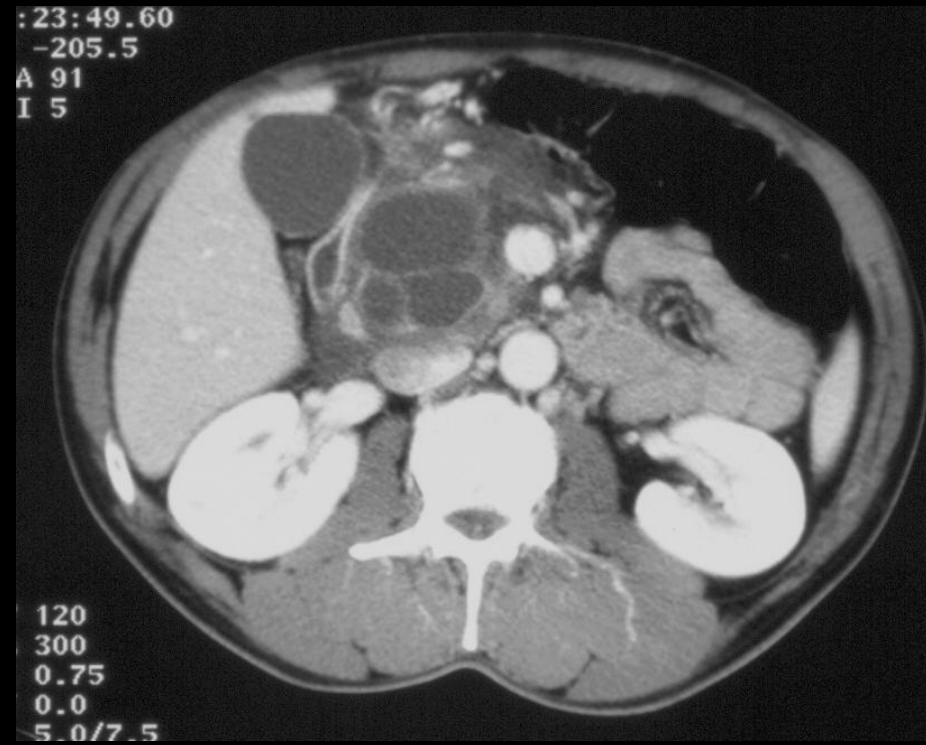
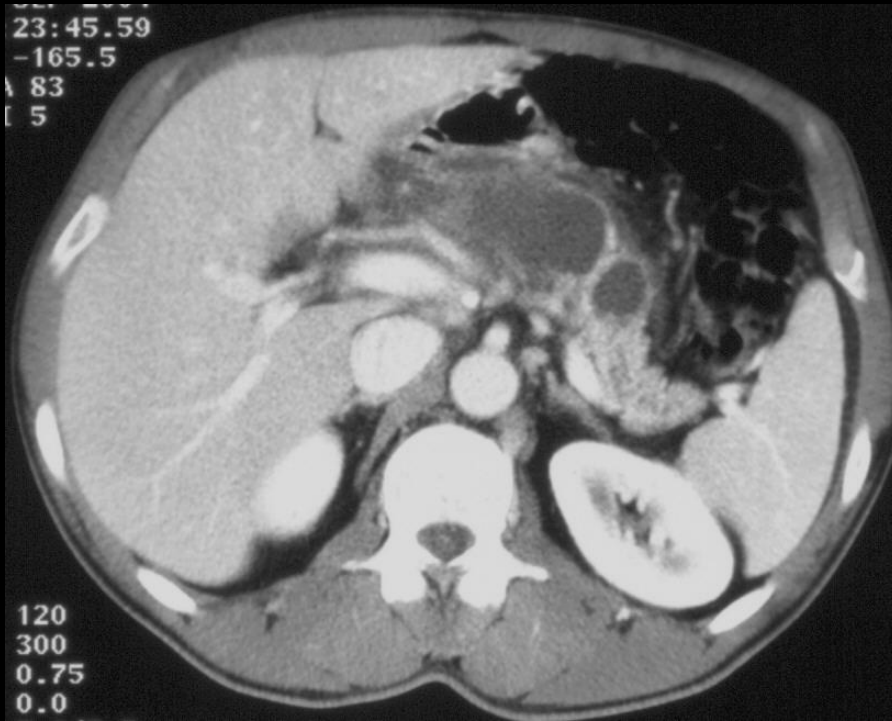


Differential diagnosis?

- Pseudocyst
- Mucinous cystadenoma
- Oligocystic form of serous cystadenoma
- IPMT
- SPN



- CT depicts a multilocular cystic lesion in the head and body of the pancreas, without calcifications.



After contrast we clearly define less than 6 cysts with more than 2 cm, with thin enhancing septa between them

Olygocystic serous cystadenoma

- At the time, when I faced this case, I didn't know this entity
- The patient had no history of pancreatitis, and I suggested the diagnosis of mucinous cystadenoma
- Fortunately for the patient he made a endoscopic aspiration, that made the proper diagnosis

Olygocystic serous cystadenoma

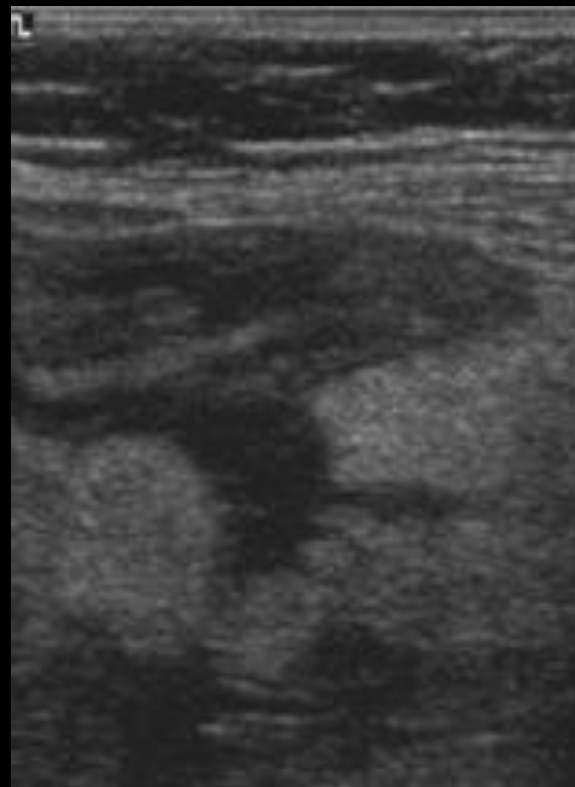
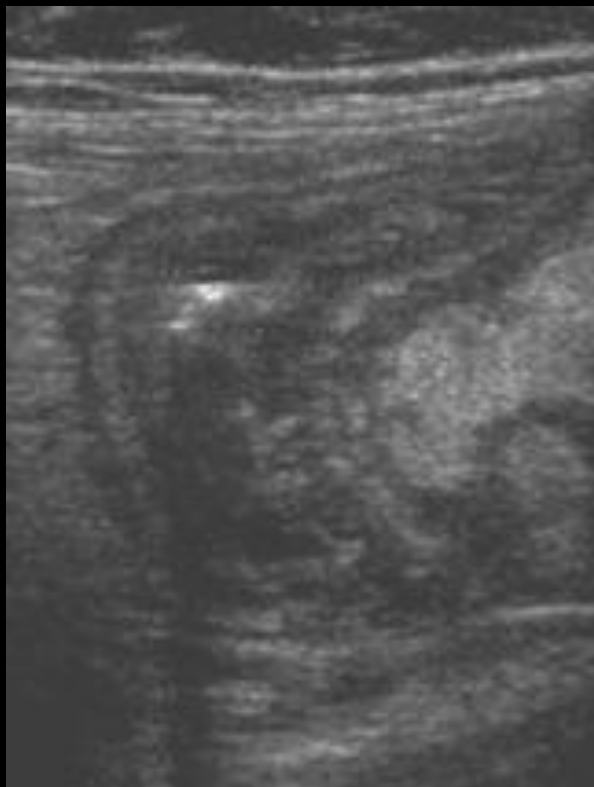
- Glycogen rich cystic lesion
- Usually located in pancreatic head
- More frequent in females. Mean age 65 years
- Constituted by a single or few cysts
- Indistinguishable from mucinous cystic tumor if there is septal enhancement

BOWEL

Case 11

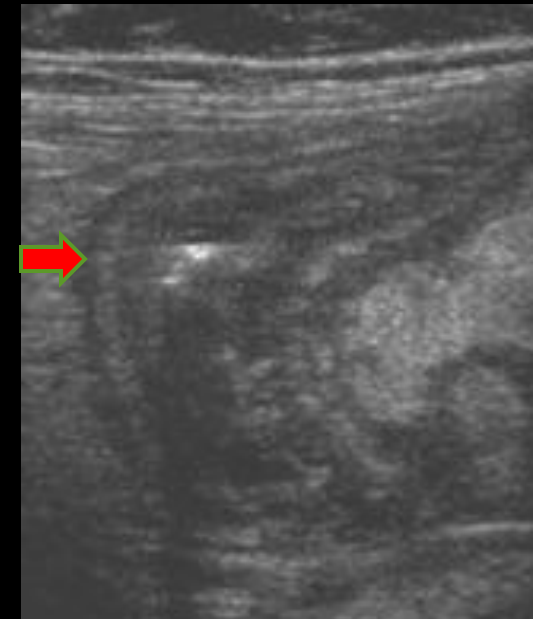- Male patient
- 30 years old
- Complaints severe peri-umbilical pain
- Appendicitis was suspected by the surgeon, who asked for an abdominal ultrasound

Ultrasound in the right quadrant

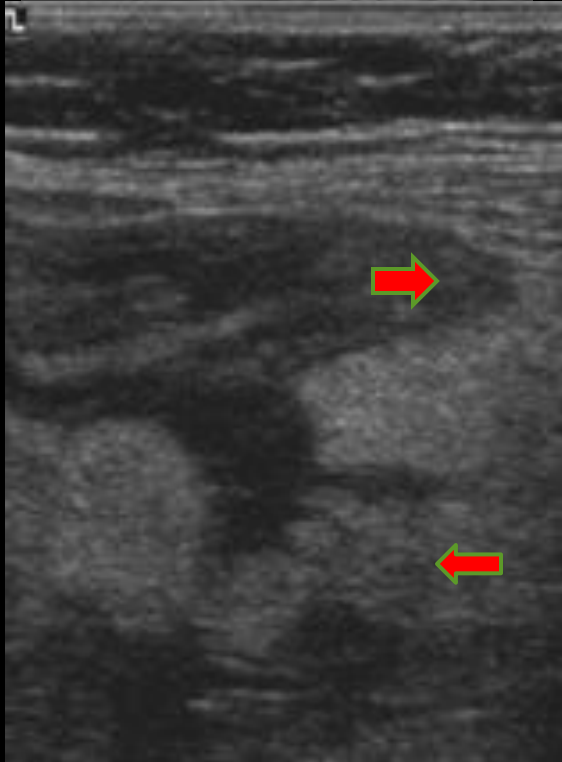


Are you sure that the patient had an appendicitis?

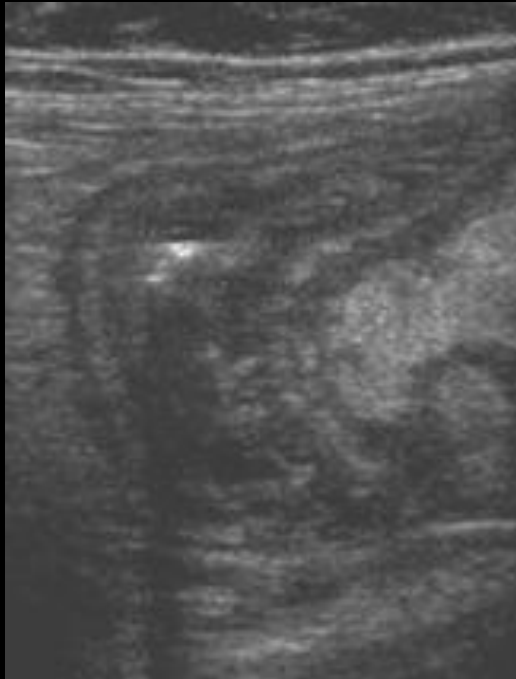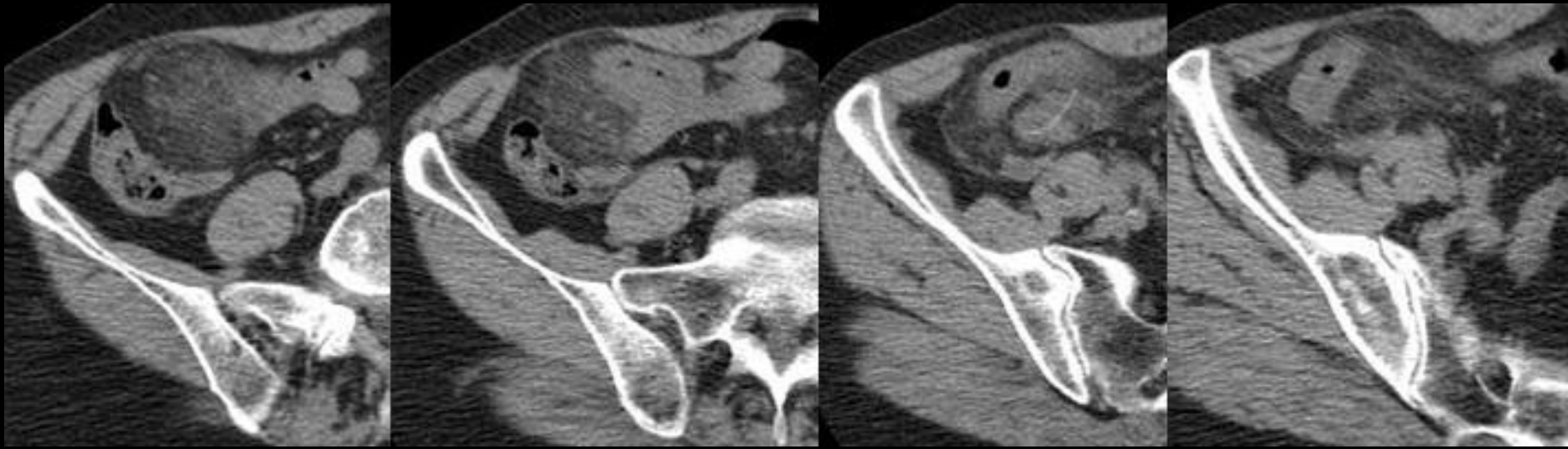
Could we state an inflammatory abdominal problem, or there is a reasonable doubt concerning a tumoral pathology



- There is a blind end bowel loop, with a multilayer thickened wall, and hyperechogenicity of adjacent fat (red arrows), that lead us to diagnosis of appendicitis.

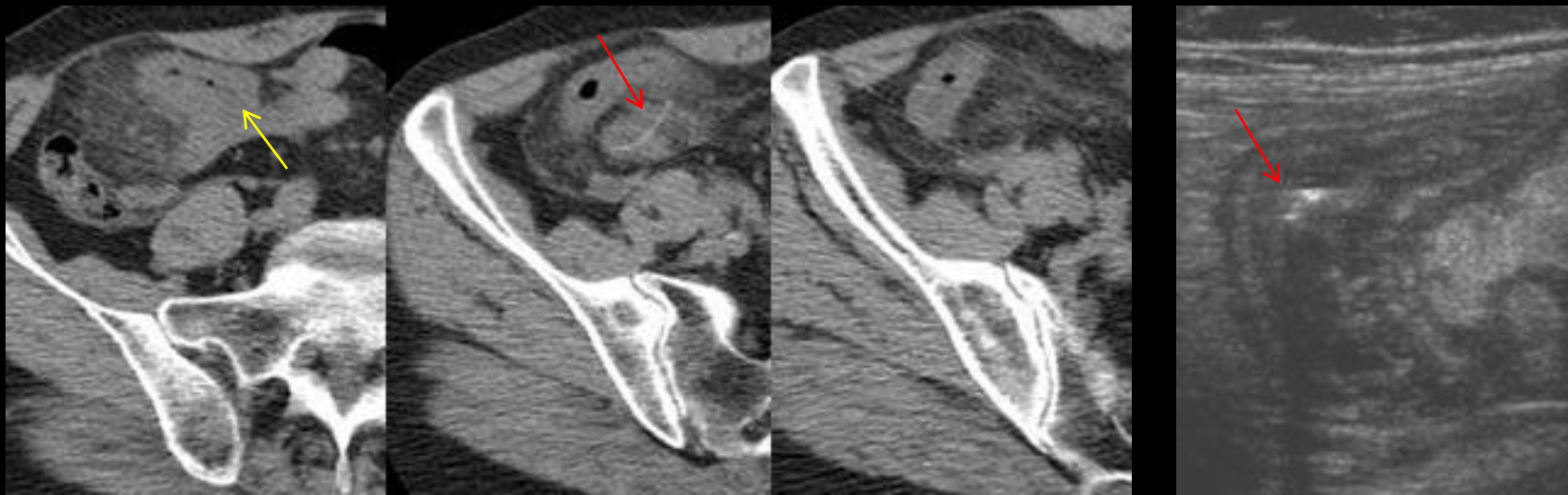


- In retrospect we have a feature that could lead us to a different hypothesis. The inflamed loop has a too large caliber for an appendix.
- Also the pain was a little bit high, but this could happen in appendicitis



Compare CT and ultrasound:

1. Note the correspondence of findings
2. Note the additional information
3. Note the finding that was not correctly appreciated



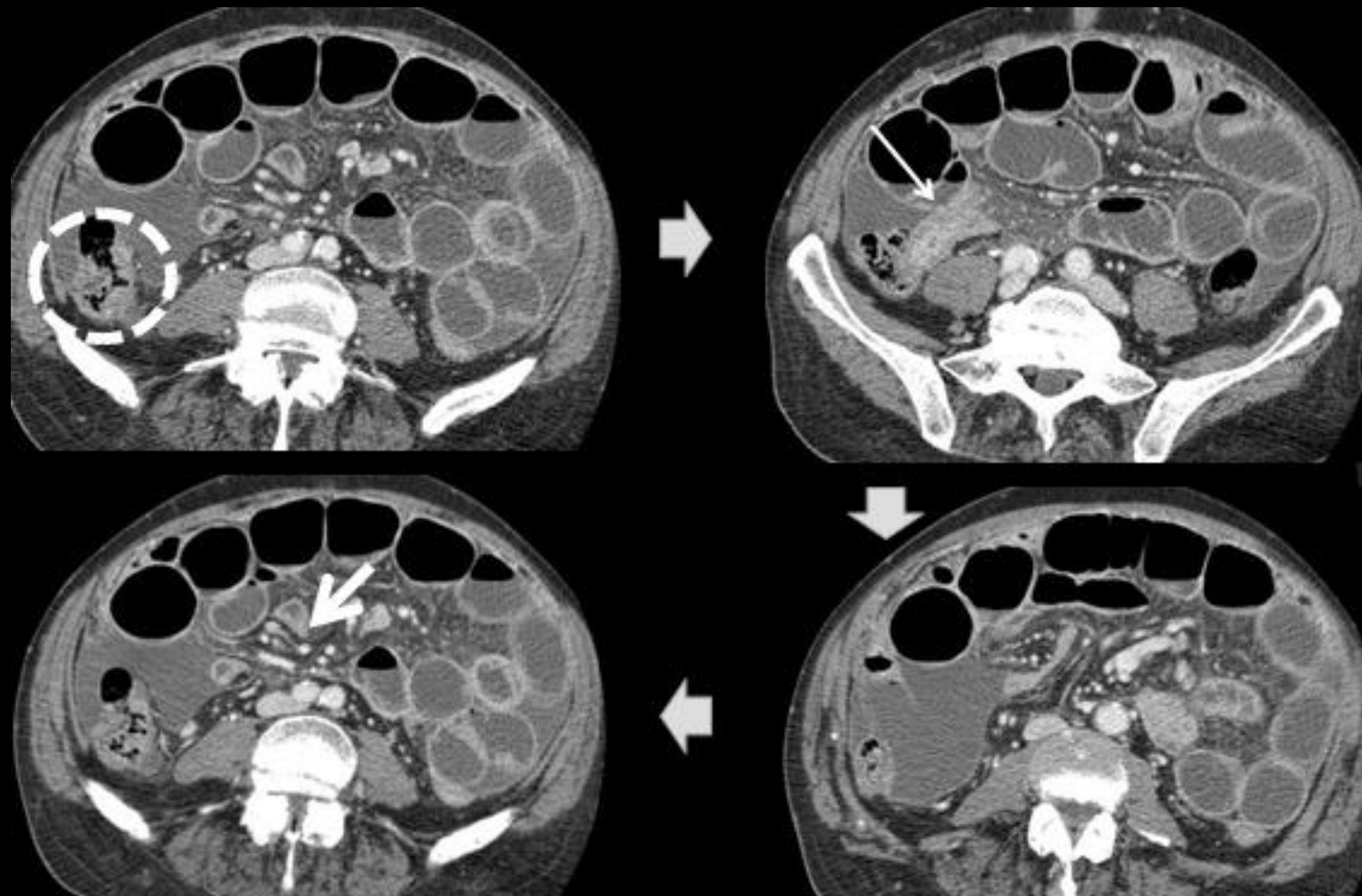
- **Red arrow** marks a fish-bone responsible for bowel perforation, that we were not able to valorize on ultrasound, not because we don't saw it, but because our mind was directed to the more common diagnosis of appendicitis.
- **Yellow arrow** points the communication between ileum and the blind end loop, that corresponds to Meckel diverticulum

Meckel diverticulitis

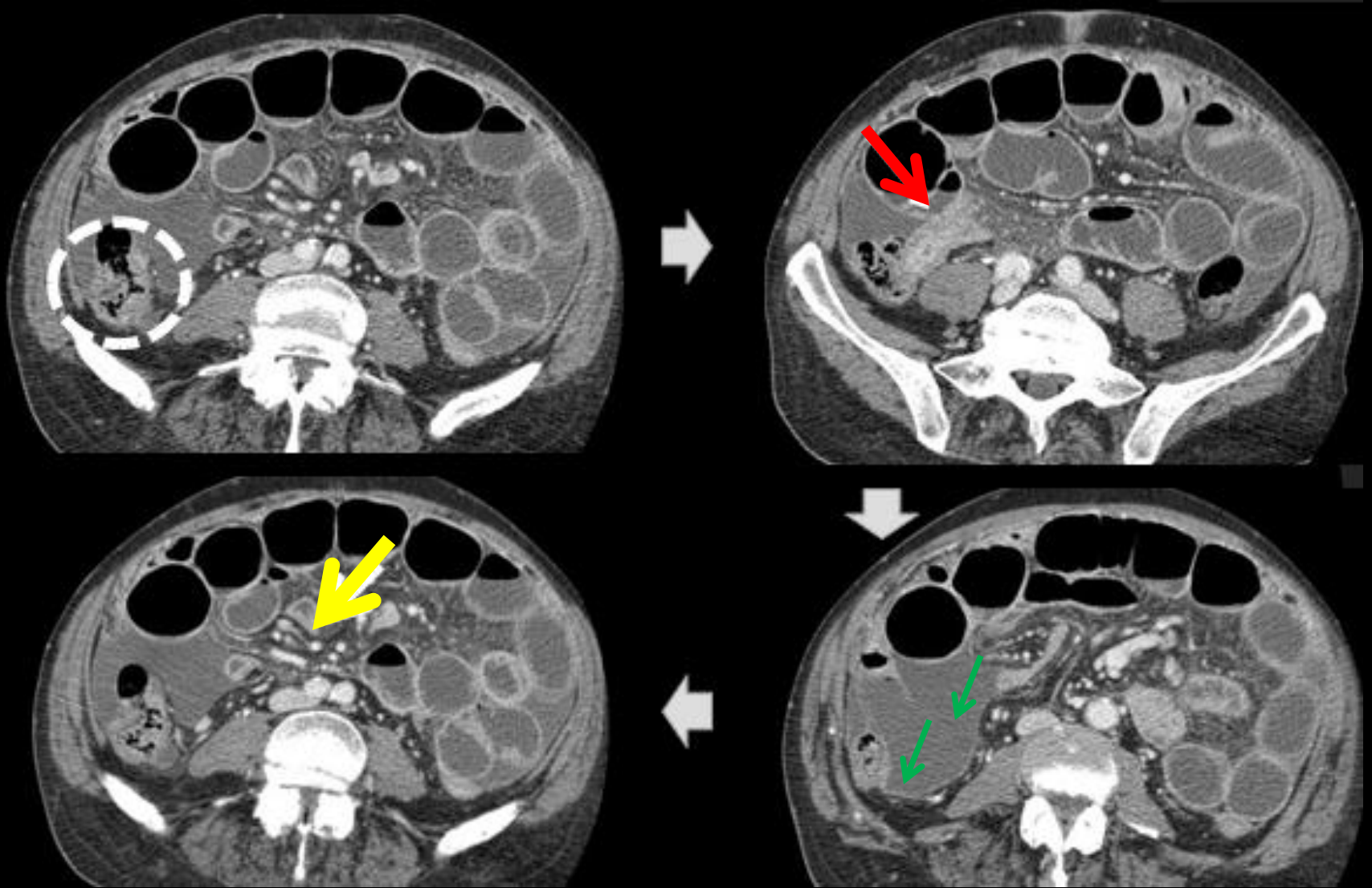
- Is the inflammation of the persistent omphalomesenteric duct
- Seen is the antimesenteric border of terminal ileum, communicating with the lumen
- 50% contain gastric mucosa
- Bleeding, intestinal obstruction and diverticulitis secondary to perforation are the principal complications
- Top differential is appendicitis

Case 12

- Male patient
- 38 years old
- African
- Chronic Diarrhea
- Severe right flank abdominal pain



White markers point several pathologic changes. What disease better integrates all changes?



- CT reveals asymmetric thickening of cecal wall (circle) and concentric thickening and layering of terminal ileum (red arrow) causing a stenosis, and consequent dilatation of bowel loops above.
- Yellow arrow marks necrotic mesenteric adenopathies.
- Green arrow points peritoneal thickening and ascites in right lower quadrant

Differential diagnosis

- Cecum and ileum thickening

- Tuberculosis
- Crohn colitis
- Lymphoma
- Amebiasis
- Yersinia infection

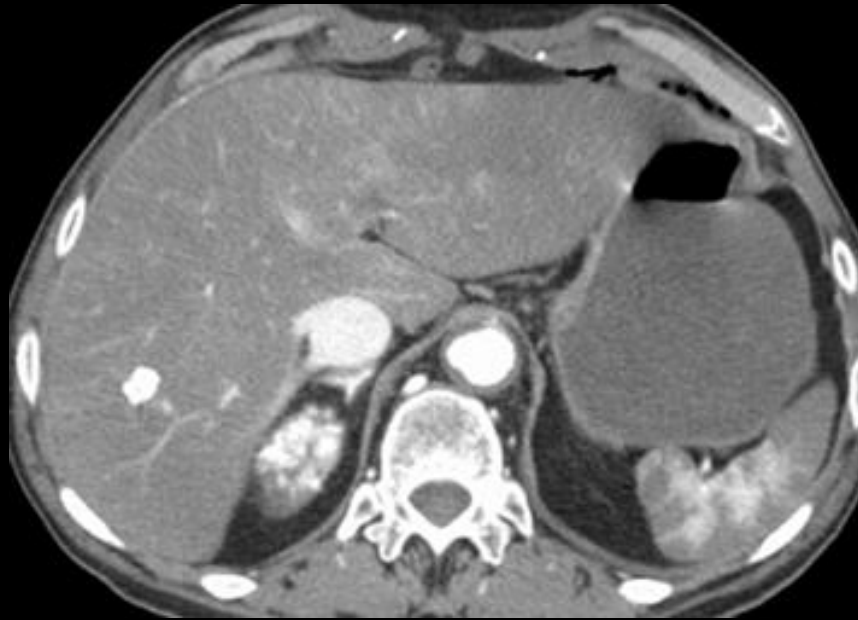
- The clue to diagnosis are the necrotic adenopathies and peritoneal thickening

Abdominal tuberculosis

- Typically GI tract tuberculosis is associated with pulmonary tuberculosis
- Disease involves cecum and terminal ileum
- The cecum can become rigid from the inflammation and scarring and appear cone shaped

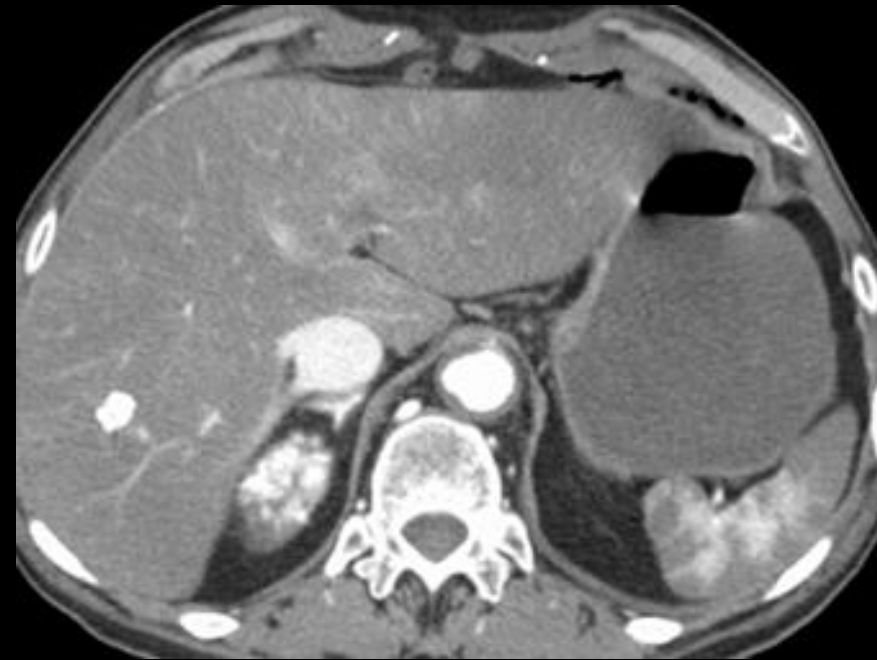Case 13

- Male, 75 years old
 - To days before had a aortic valve repair
 - Maintained hemodynamic stable in the post-operative period with amines.
-
- Sudden fibrillation and abdominal pain
 - No hypotension in the acute setting



- Which are the abnormal findings in this image, acquired 70 s after contrast administration?

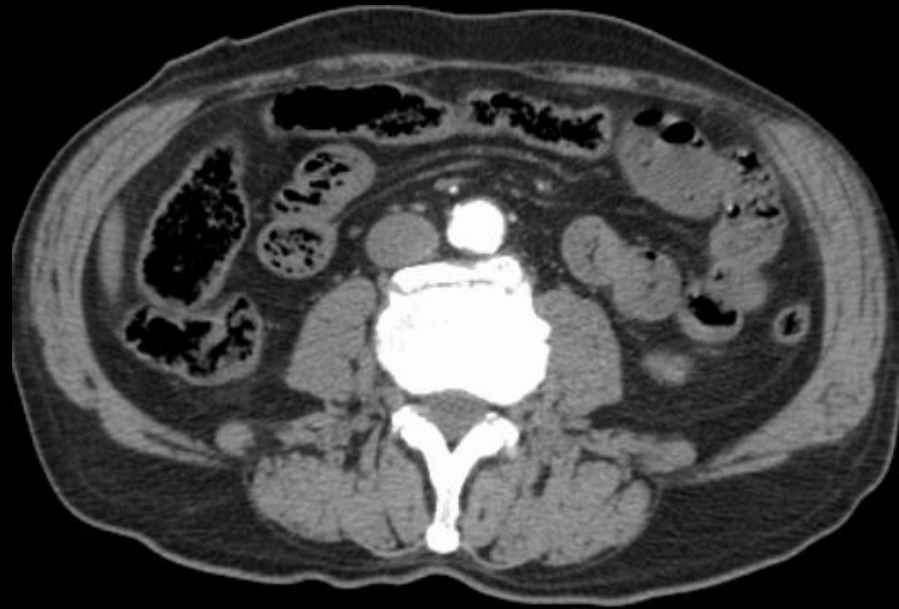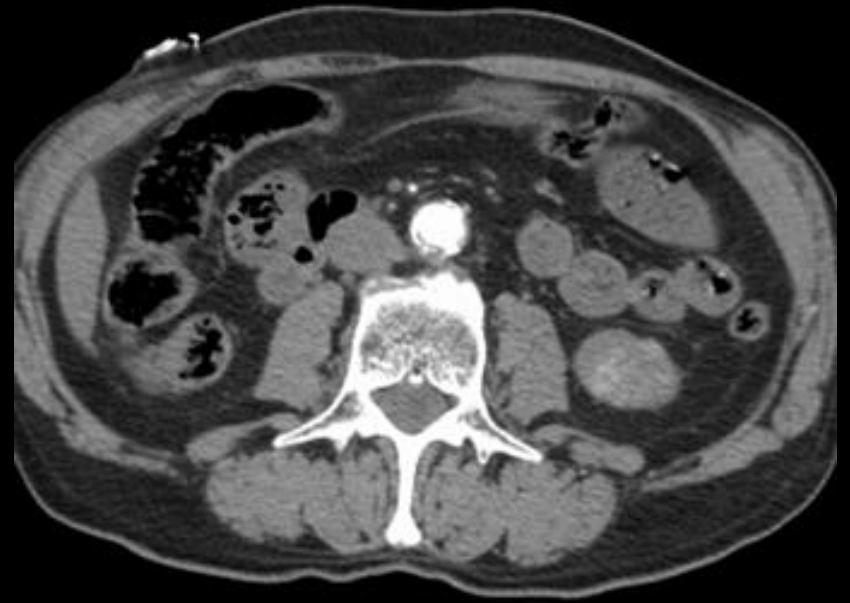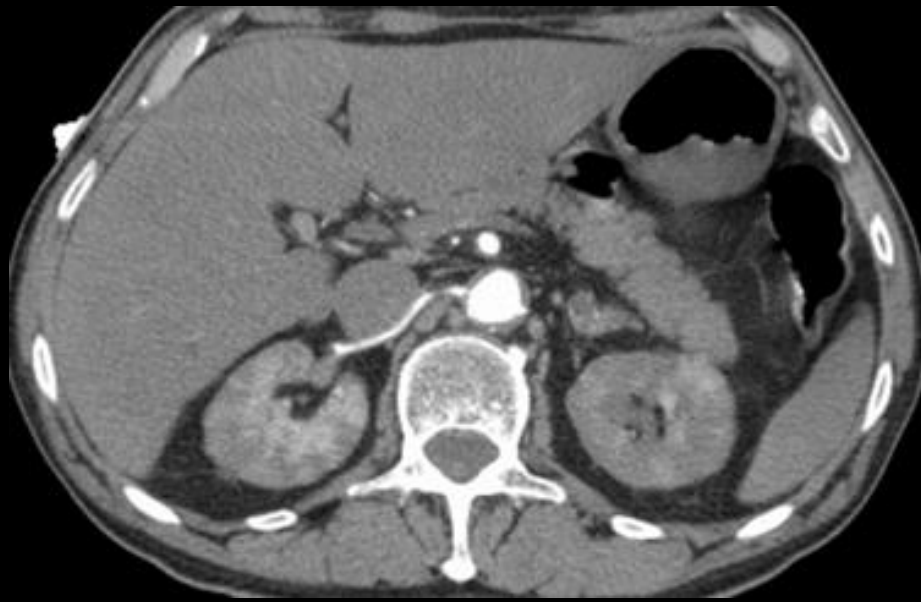For a portal phase image there are various abnormalities:



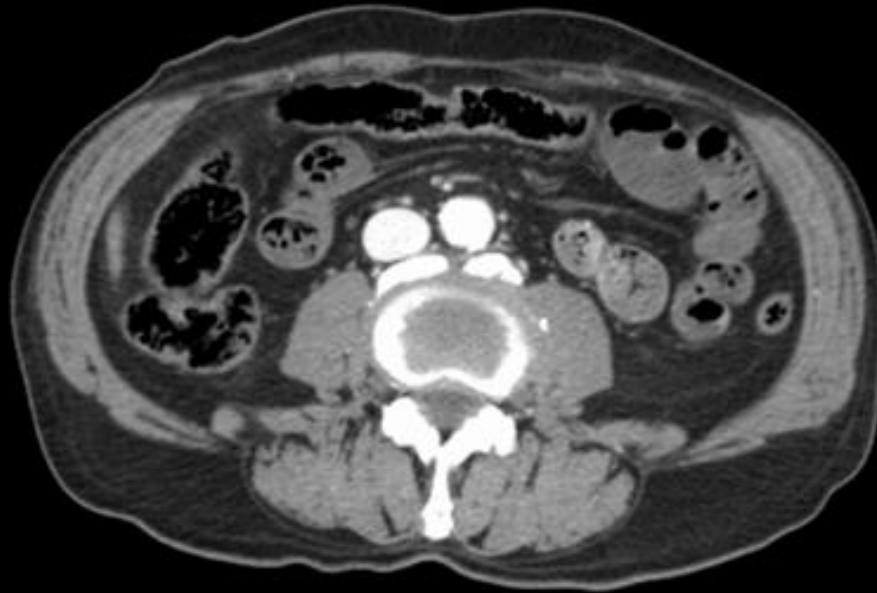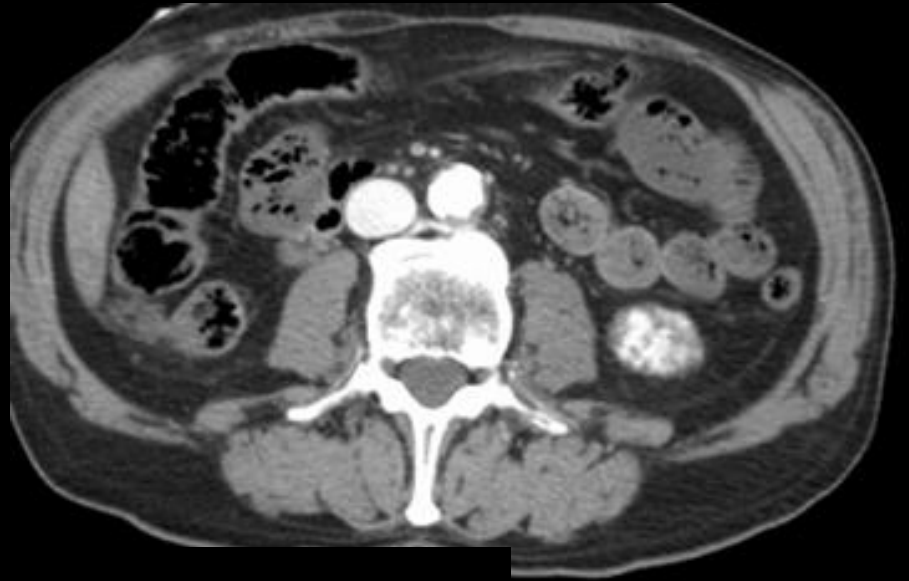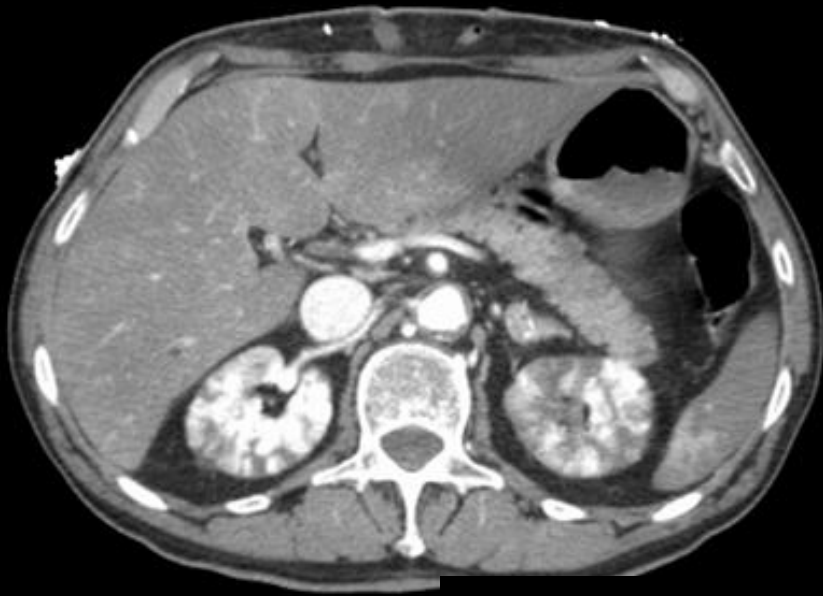1. Similar attenuation of aorta and vena cava
2. Higher attenuation than normal in aorta and vena cava
3. Heterogeneous splenic enhancement
4. Heterogeneous renal enhancement, with globular morphology
5. Hyperattenuating right adrenal gland
6. Liver hypoattenuation

In next slides

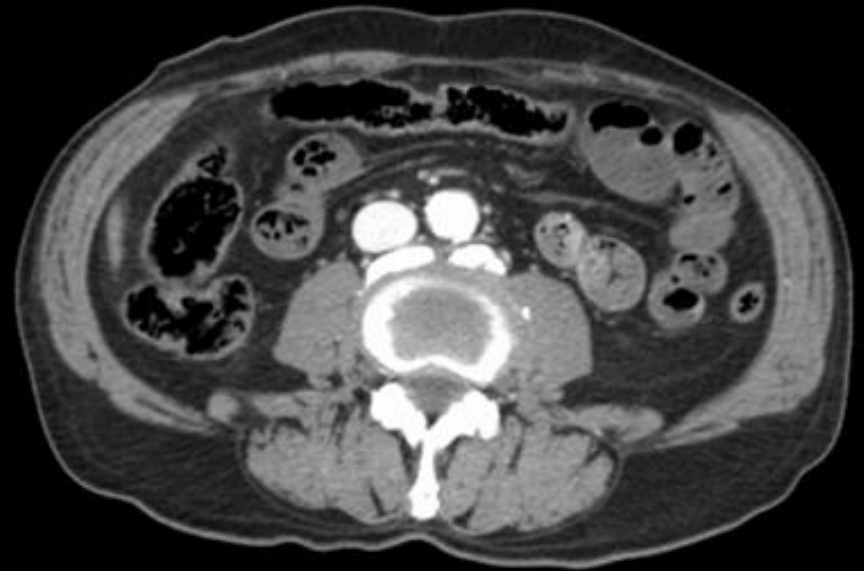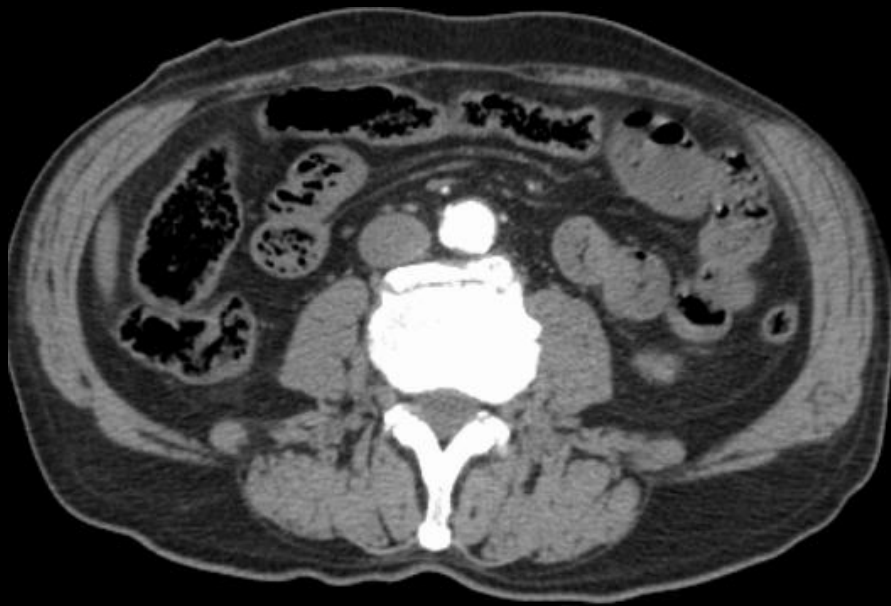- The adrenal gland suggests what kind of problem?
- Look right renal artery
- Analyze mesenteric artery
- Bowel wall enhancement
- Colon enhancement
- Pancreatic enhancement



Arterial phase



Portal phase



Compare the attenuation of bowel wall between arterial and portal phase

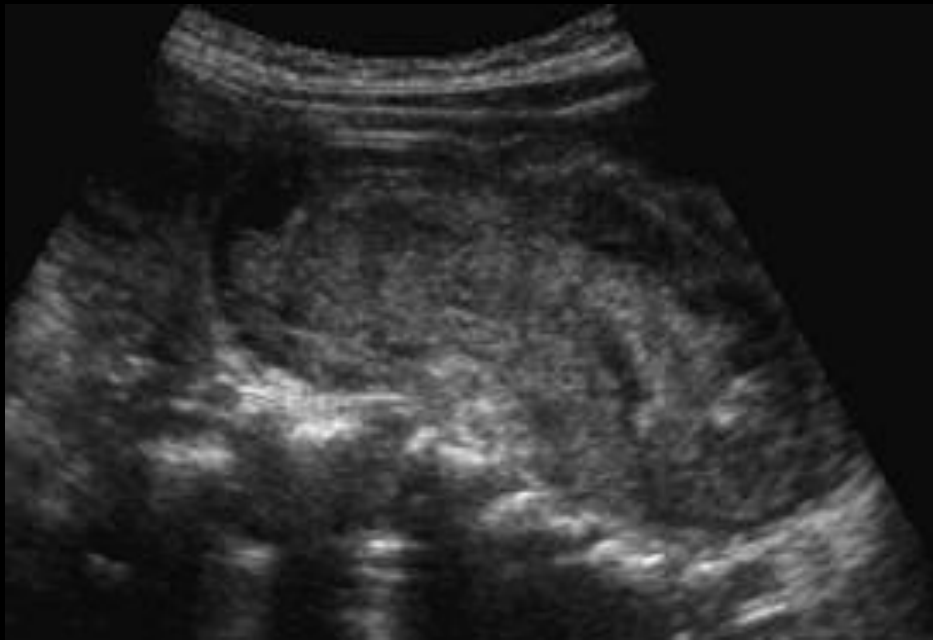- Its crucial to proceed to a systematic organization of findings
 - Systemic hypoperfusion
 - Progressive enhancement between phases of contrast in pancreas, liver, bowell wall
 - Adrenal hyperenhancement
 - Reduced caliber of renal and mesenteric artery
 - Systemic micro-embolization
 - Multiple renal areas of absent perfusion
 - Absence of great vessel vascular ocllusion

Small bowel hypoperfusion and microembolization

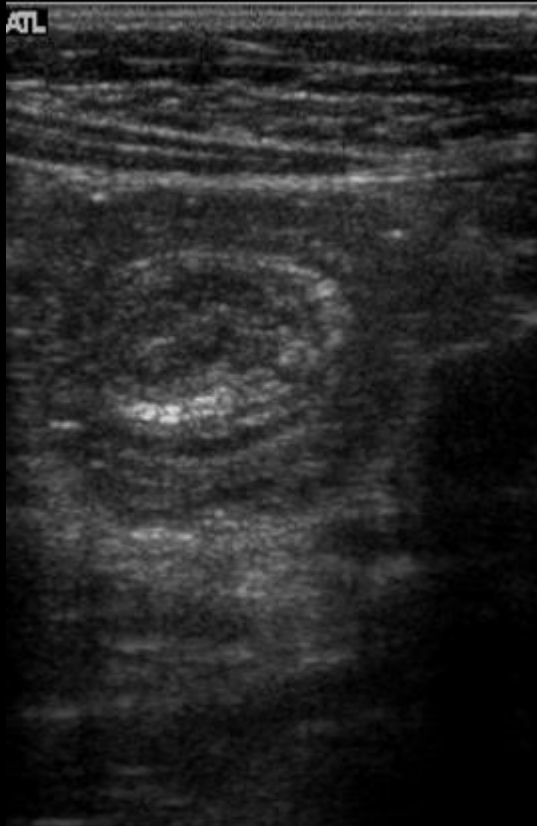
- Non-obstructive ischemia is a condition associated with systemic hypoperfusion
- There is

Case 14

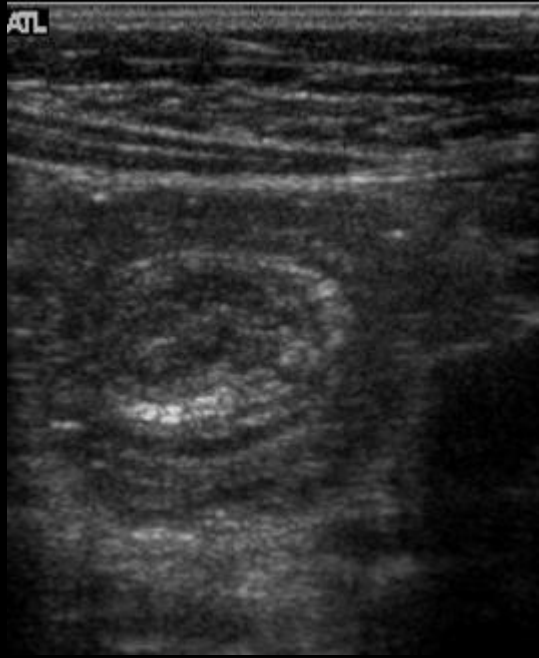
- Female
- 37 years old
- Right lower quadrant pain
- Tenderness
- Blumberg negative



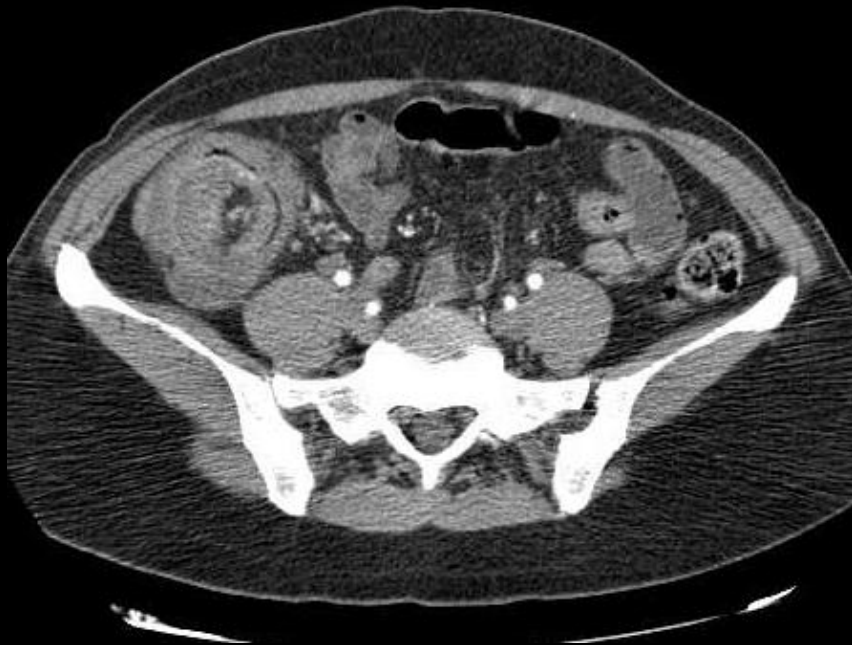- Ultrasound image in right lower quadrant.
- Drive or differential diagnosis?



- Does the orthogonal plan changes it?



- The target appearance seen on the ultrasound corresponds to a intussusception.
- CT was done to exclude a leading mass.
- Despite ultrasound would be sufficient to make diagnosis, in the adult is necessary to exclude an associated mass.

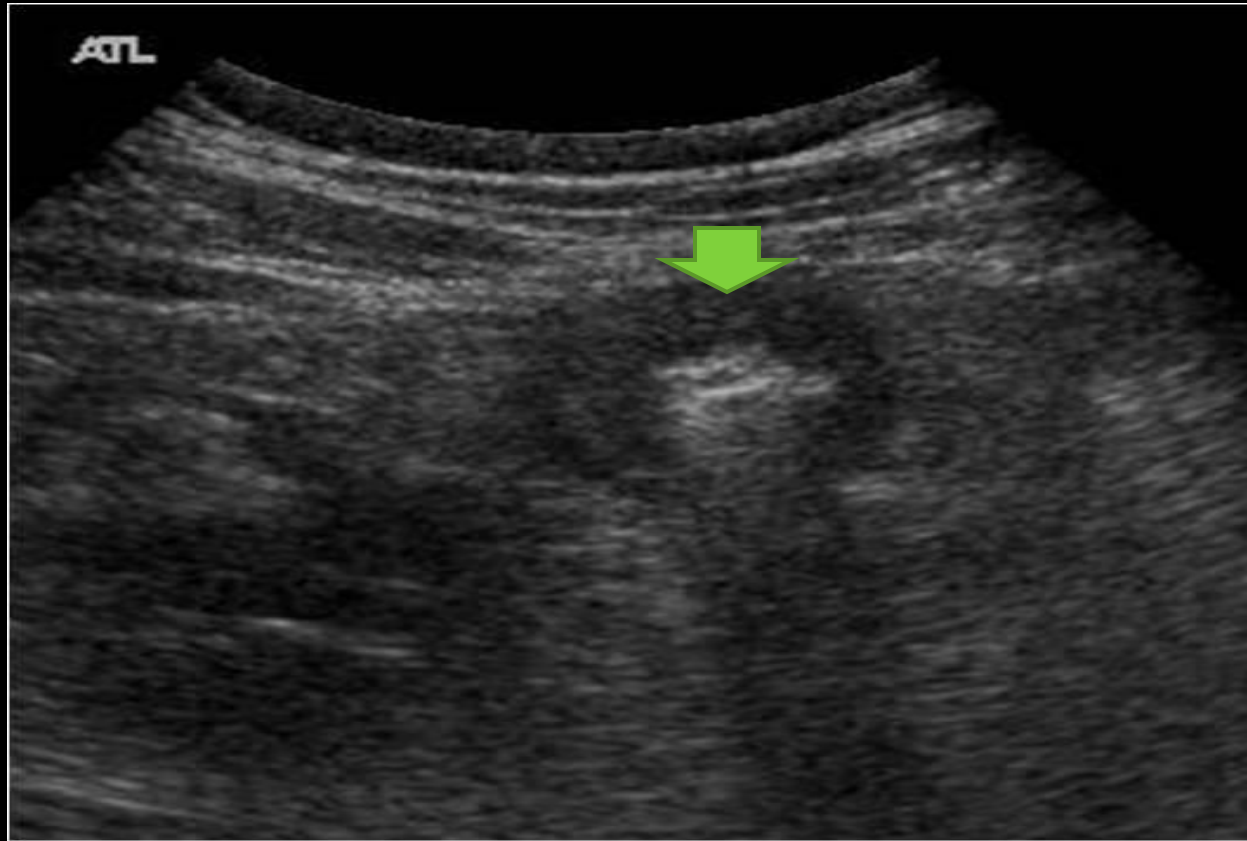


Intussusception

- Intussusception is classified into two types in adults:
 - ▣ The more common short segment intussusception is typically not obstructing and not caused by a lead mass, also had a transitory compartment
 - ▣ Long segment intussusception is caused by a lead mass and obstructive

Case 15

- Male
- 30 years
- Haematuria
- Abdominal pain
- Skin rash



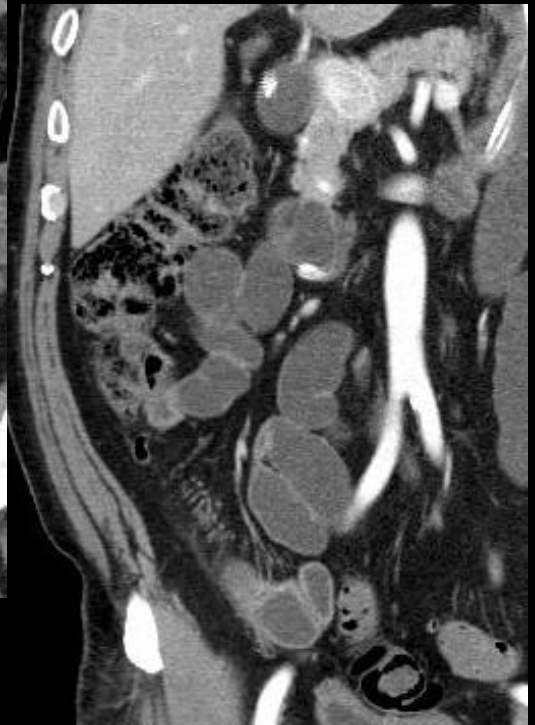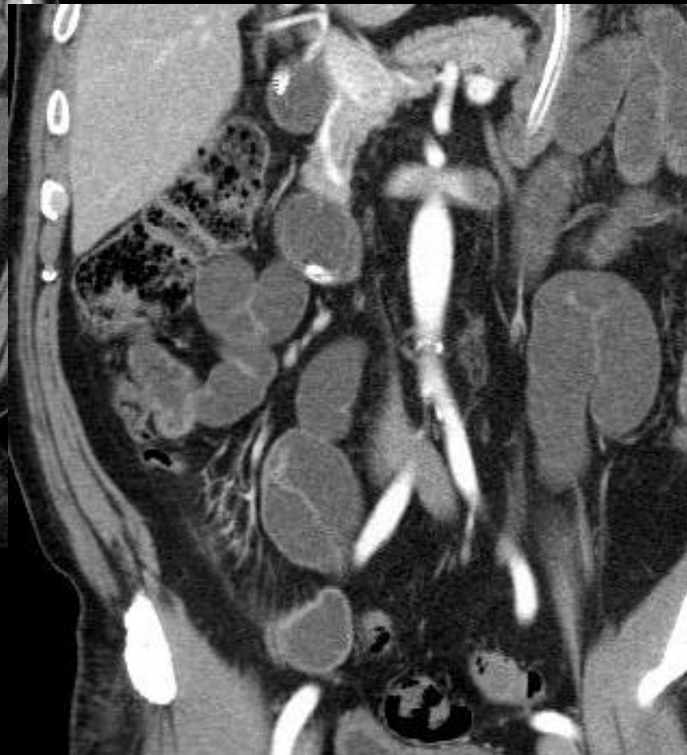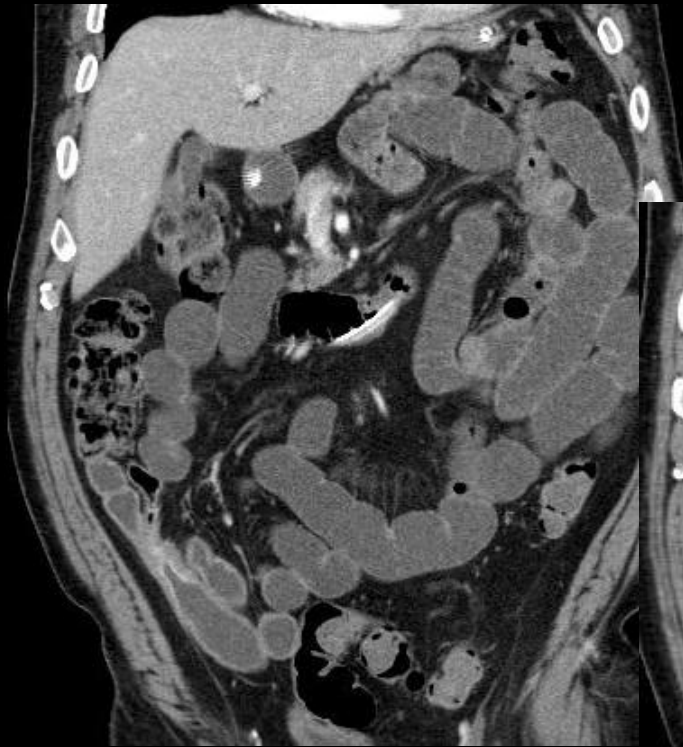
Abdominal ultrasound depicted a small bowel loop in right lower quadrant with thickened non stratificated wall, and without increased echogenicity of peritoneal fat adjacent to it.

There were no collections or free abdominal fluid.

Small bowel loops were not distended.

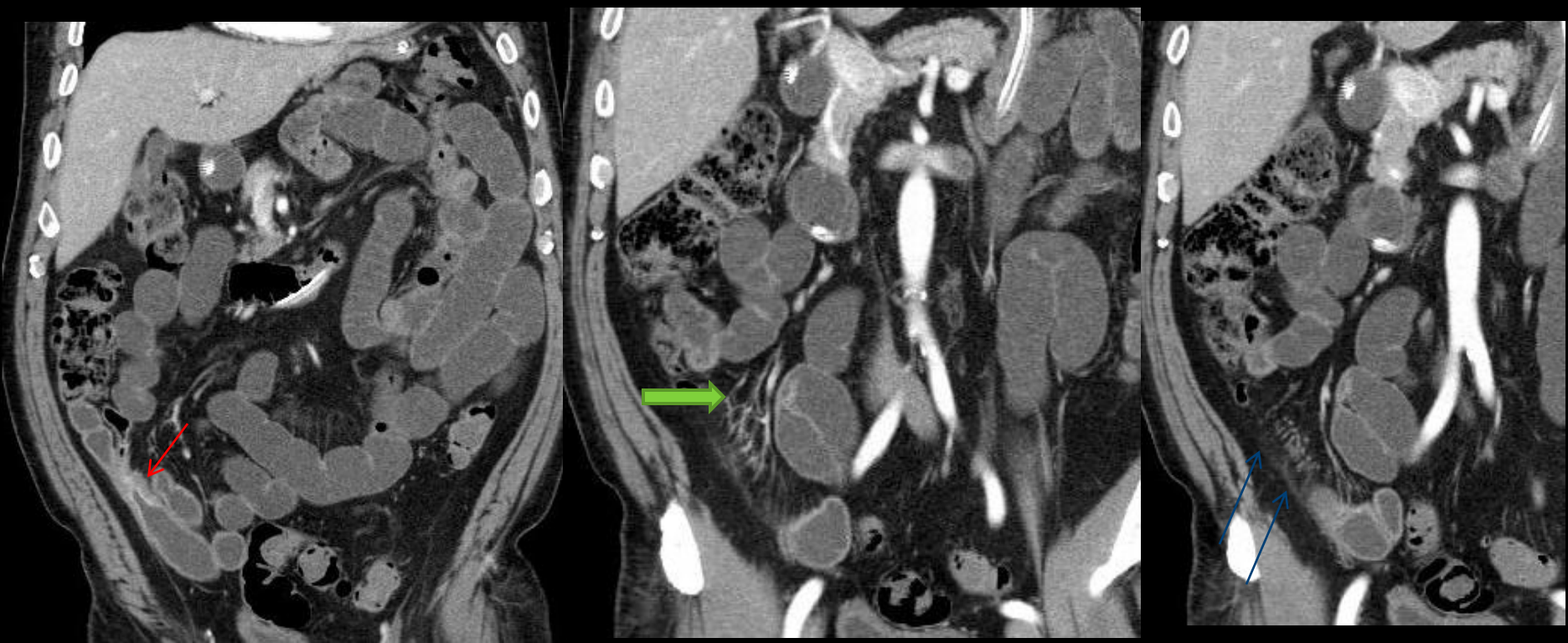What should the patient do to characterize the abnormalities?

- Abdominal CT



But we have done a CT enteroclysis in the next day.

What are the findings and the differential diagnosis?



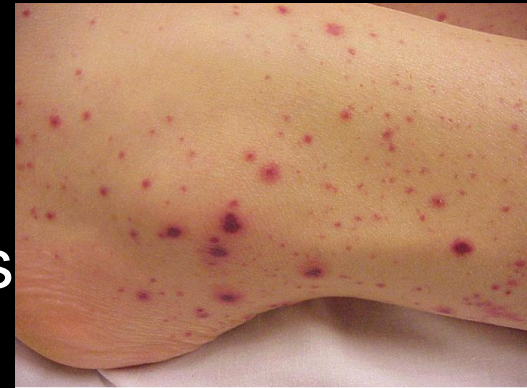- **Red arrow** marks the terminal ileum stenosis, with mucosal intense enhancement, without shoulders in the transition to normal wall. No other wall changes were seen the bowel.
- **Blue arrow** points fat densification in right lower quadrant
- **Green arrow** indicates vasa recta dilatation.

Differential diagnosis

- Inflammatory bowel disease (IBD) is the first diagnosis if the patient had not a diffuse skin rash that resembled a purpura.
- In fact pyoderma gangrenosum could be associated with IBD, but is a more localized form of skin disease.
- A bowel neoplasm, like a carcinoma or lymphoma, should not have associated inflammatory signs in vessels and fat

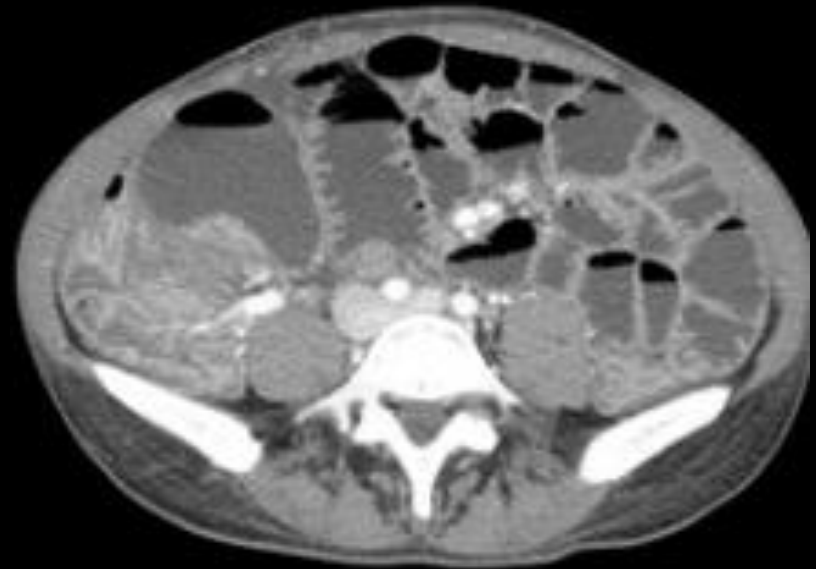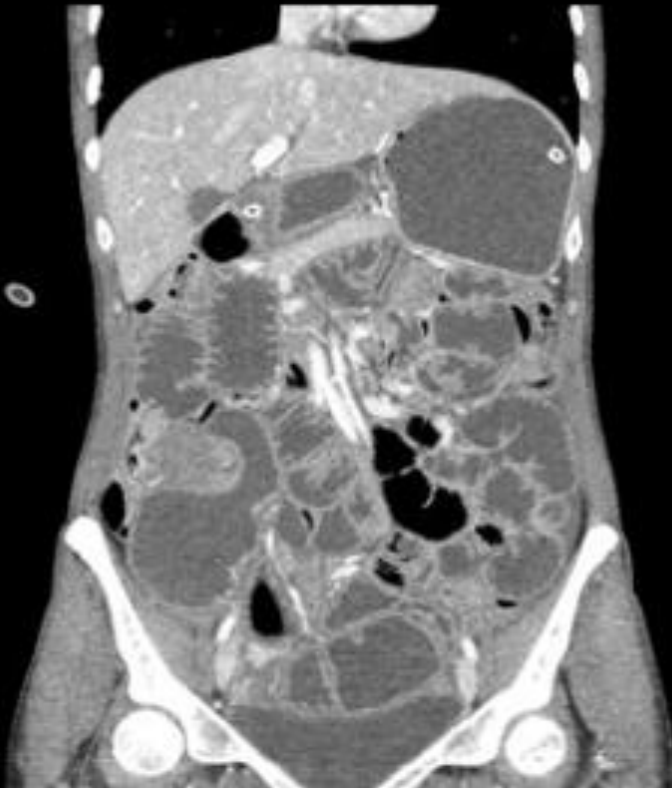Henoch-Schonlein purpura

- Is a hypersensitivity small vessel vasculitis
- Manifestations include purpuric rash, abdominal pain, renal involvement and arthritis
- Severe cases may manifest as hematemesis, melenas and intestinal obstruction secondary to intussusception
- Radiologic findings are nonspecific, and mimic inflammatory bowel changes.
- The purpuric rash is the clue to the diagnosis



Case 16

- Female
- 35 years old
- Abdominal pain with 8 months of evolution
- Marked abdominal distension



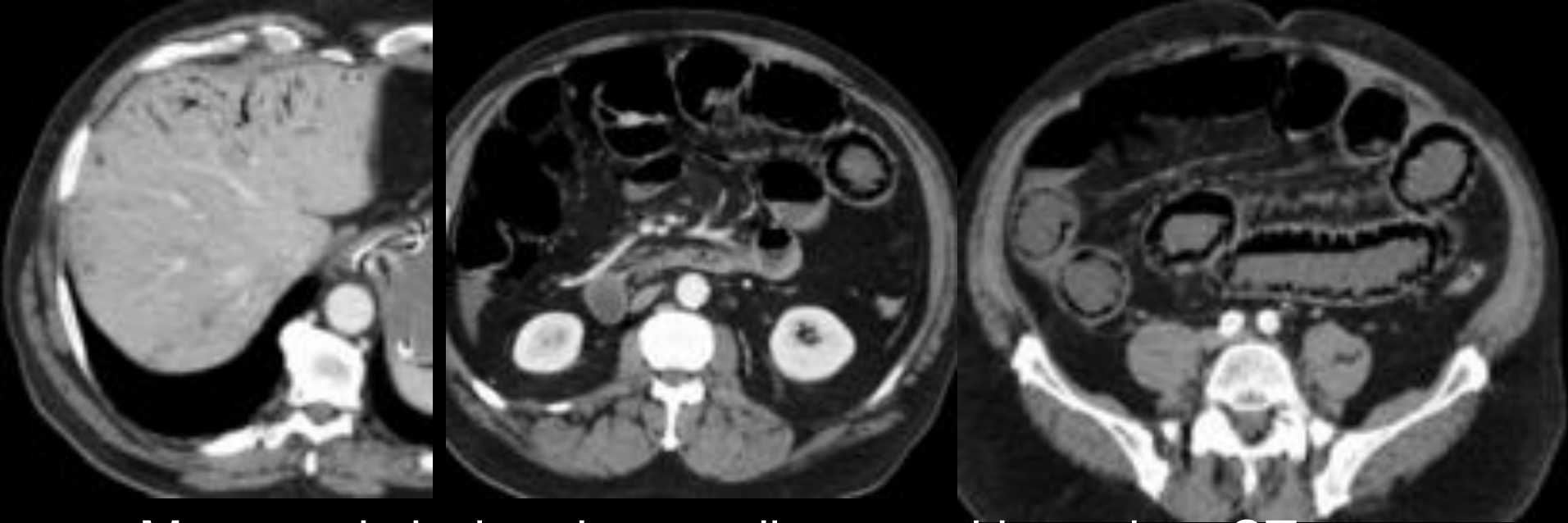
Drive a short list of possible diagnosis?

Endometriosis of terminal ileum

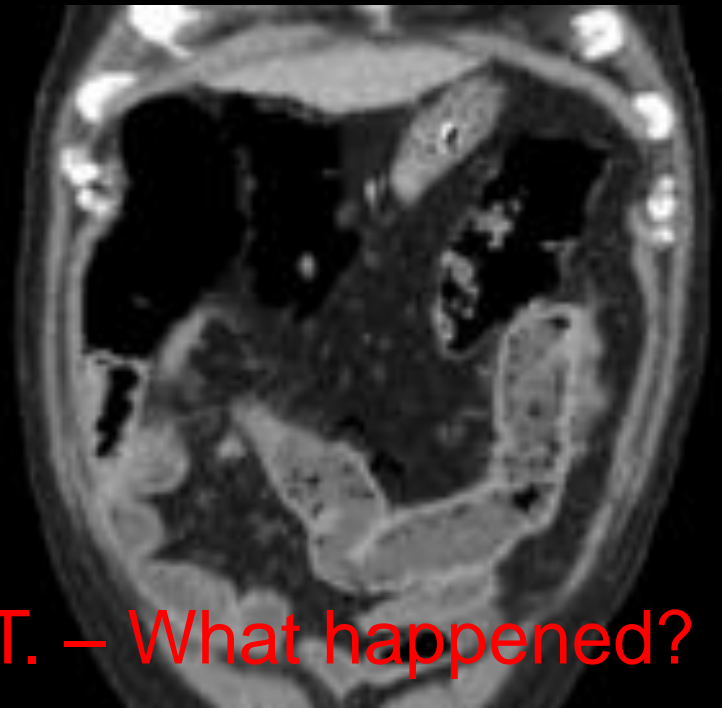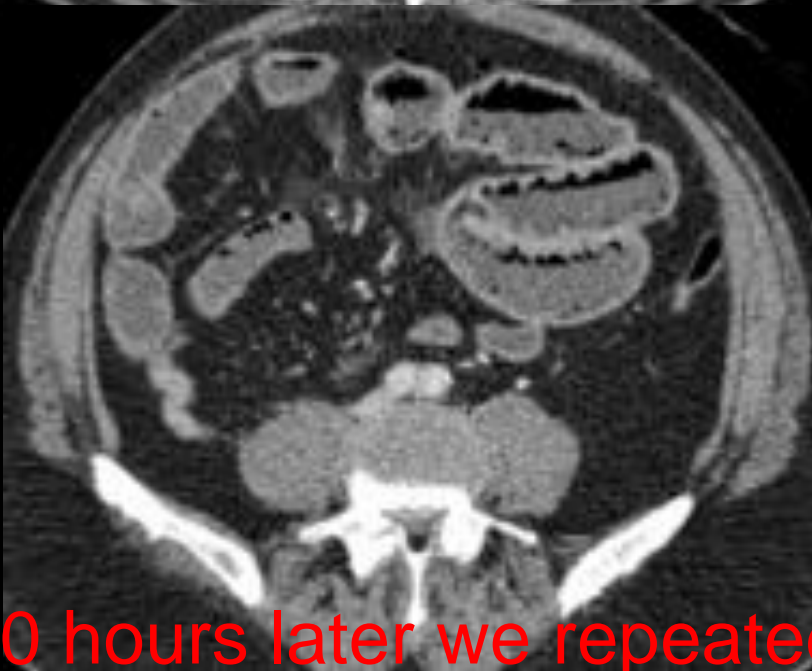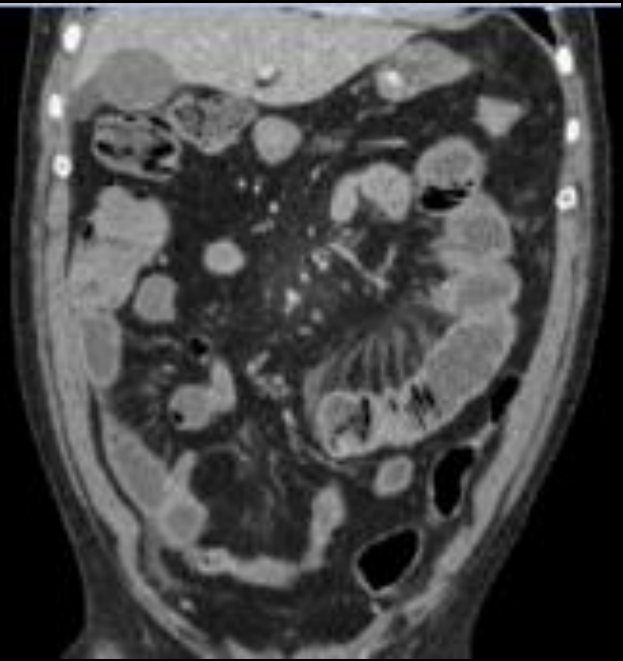
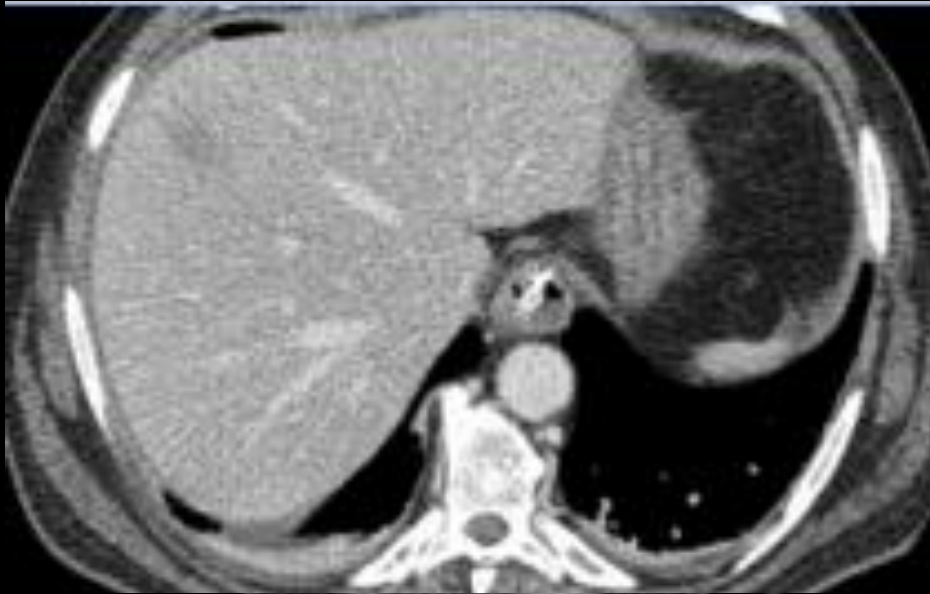- Well I thought that it could be a lymphoma or carcinoma.
- If I had done an unenhanced acquisition, maybe the diagnosis could have been stated
- In fact in a young female this should be a constant hypothesis

Case 17

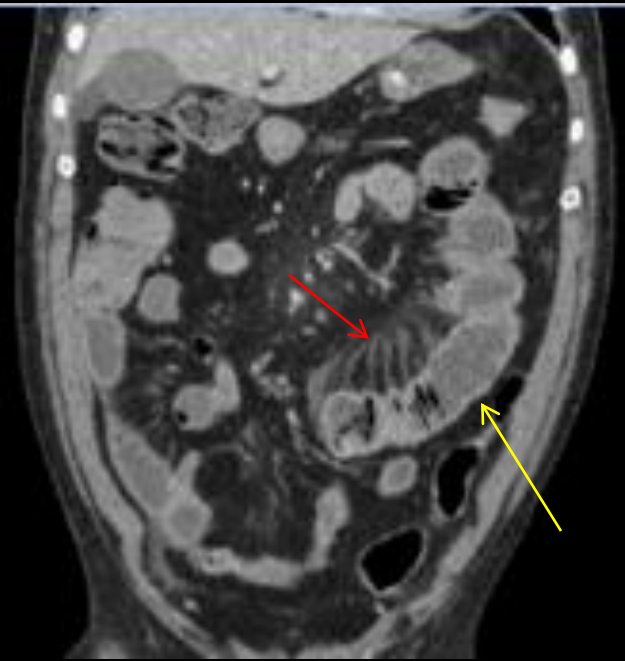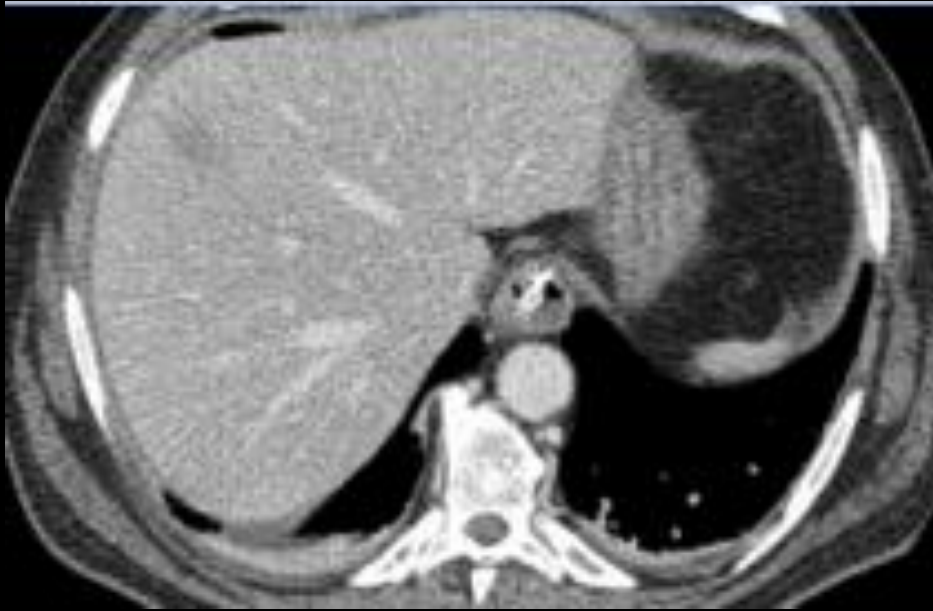- Male
- 80 years old
- Father of a medical doctor
- Intense abdominal pain



- Mesenteric ischemia was diagnosed based on CT images in a peripheral hospital
- Patient went to surgery. No ischemia was not, only slight bowel edema
- The son claimed that is father should be sent to our hospital



10 hours later we repeated CT. – What happened?



- No gas in portal veins
- No gas in bowel wall
- Engorged mesenteric vessels, slight densification of mesenteric fat (red arrow)
- Distended bowel lumen (yellow arrow)
- Enhancing and slight thickened bowel wall (yellow arrow)

- At first I thought that now I was seeing reperfusion changes

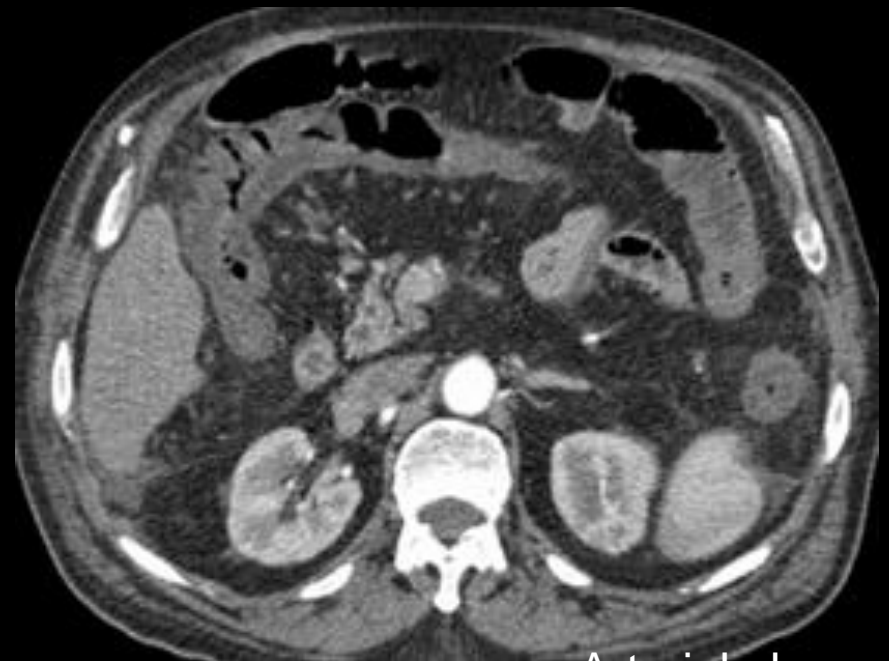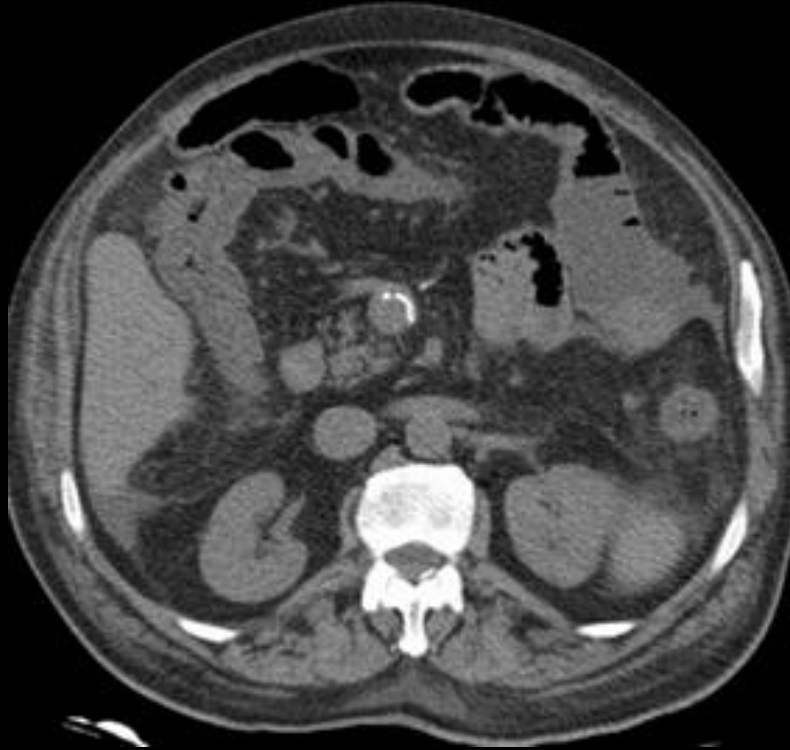- But luckily before I end my report, the son came to me with the CD of the first CT
- Then in the middle of the conversation, told me that the patient extracted a colon polyp in the day before
- Then, thanks to a correct clinical information, the diagnosis of bowel pneumatosis secondary to a medical procedure was confidently done

Benign intestinal pneumatosis

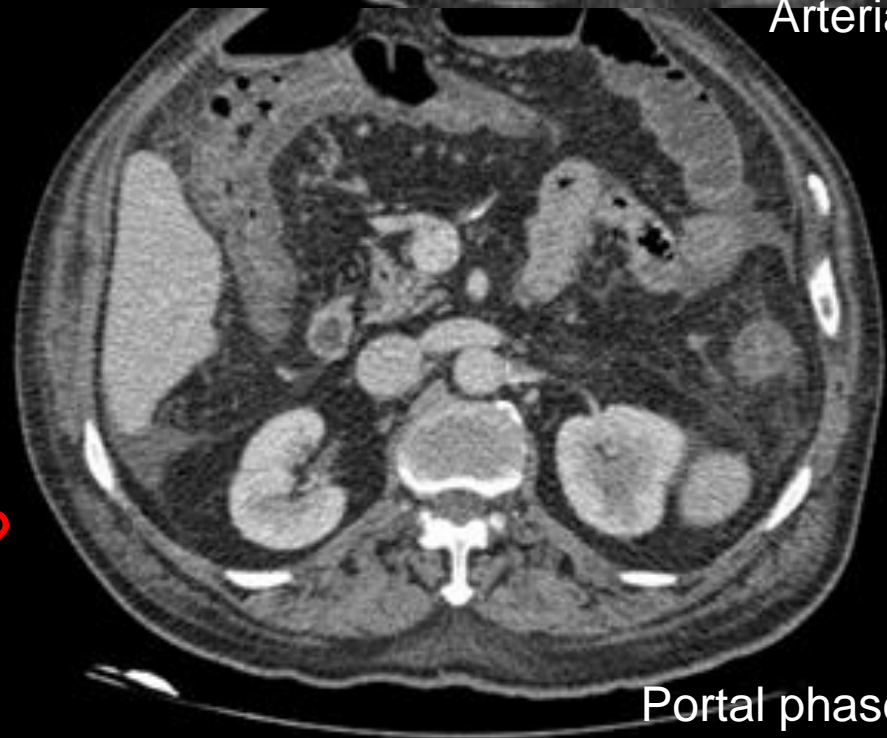
- It is generally accepted that ischemia is the most common cause of pneumatosis
- However other conditions without dismal prognosis are increasingly observed.
- They are mainly secondary to mucosal damage (biopsies, diverticulitis, graft versus host disease, chemotherapy, ulcerative colitis and cancers)
- Primary pneumatosis intestinalis can also be cause of portal vein gas

Case 19

- Female
- 85 years old
- Brought to urgency by cardiogenic syncope
- After some hours intense abdominal pain and rectal bleeding

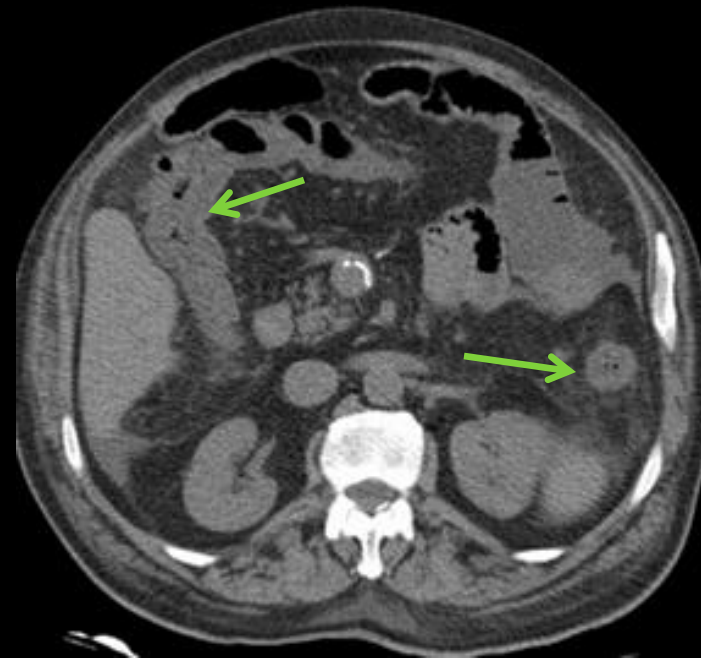


Arterial phase

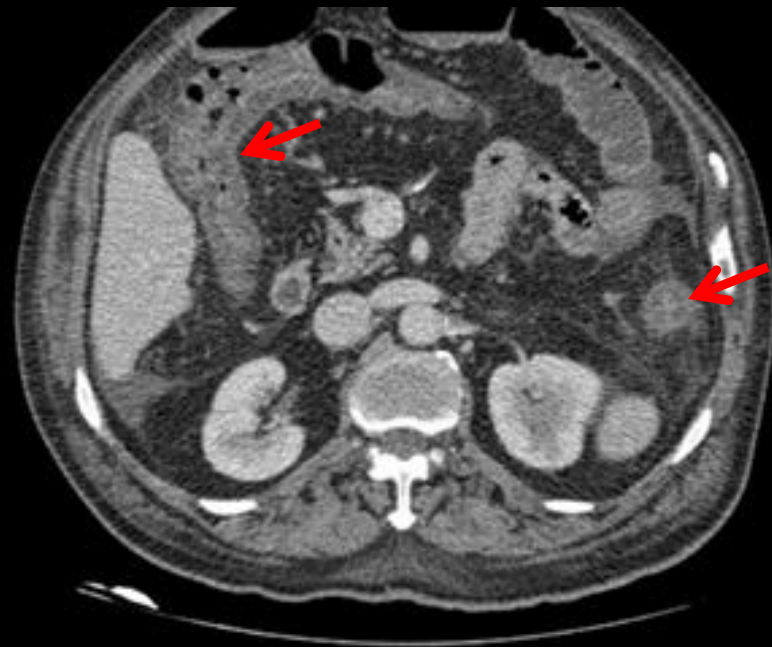

Portal phase

Important findings?
Differential diagnosis?



- Right and left colon wall thickening (green arrow)
- Before contrast colon mucosa and serosa slight hyperdense (green arrow)
- No enhancement of colon wall after contrast (red arrow)
- No small bowel changes
- Small volume of ascitis



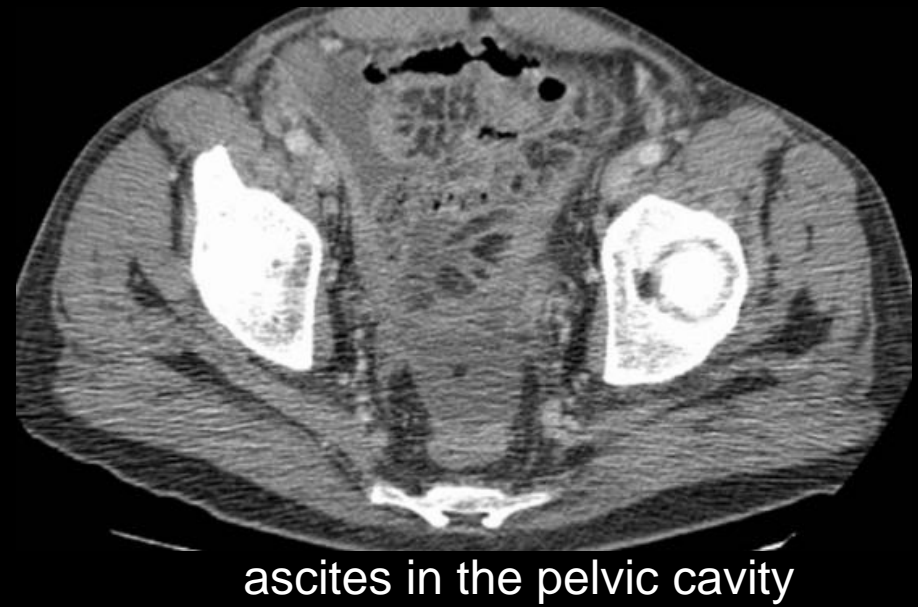
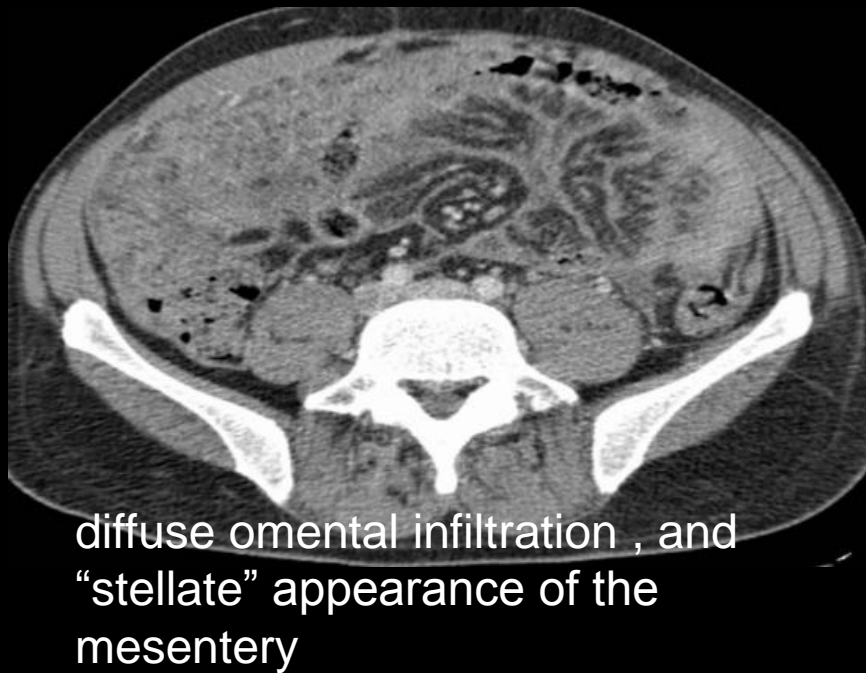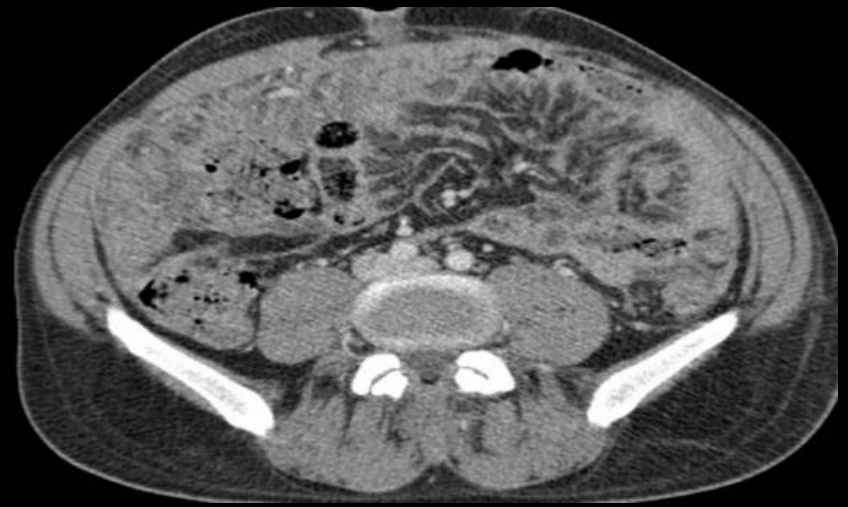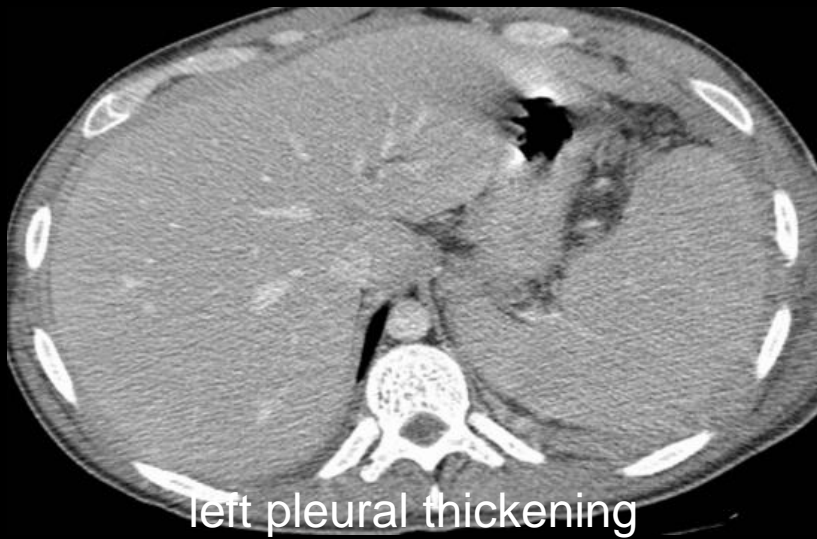Ischemic colitis

- Is a common cause of abdominal pain in elderly
- Usually results from hypoperfusion secondary to heart failure, hemorrhagic or septic shock
- The extent and severity may vary with the cause and vessels involved, therefore colitis can be diffuse or segmental
- Wall thickening and absence of enhancement are the imaging hallmarks

PERITONEUM

Case 20

- 40 years old female
- HIV positive
- Intense pleuritic and abdominal pain
- Fever



Differential?

- Malignant peritoneal mesothelioma;
- Peritoneal carcinomatosis;
-
- *Pseudomyxoma peritonei*;
- Peritoneal lymphomatosis;
- Tuberculous peritonitis.
- Mesothelioma should be suspected in cases with concomitant presence of lung disease or pleural plaques
- Pseudomyxoma peritonei should be considered when peritoneal disease has predominantly low attenuation
- Tuberculosis is associated with of low-attenuating lymphadenopathy, and/or mural thickening of the terminal ileum and cecum.

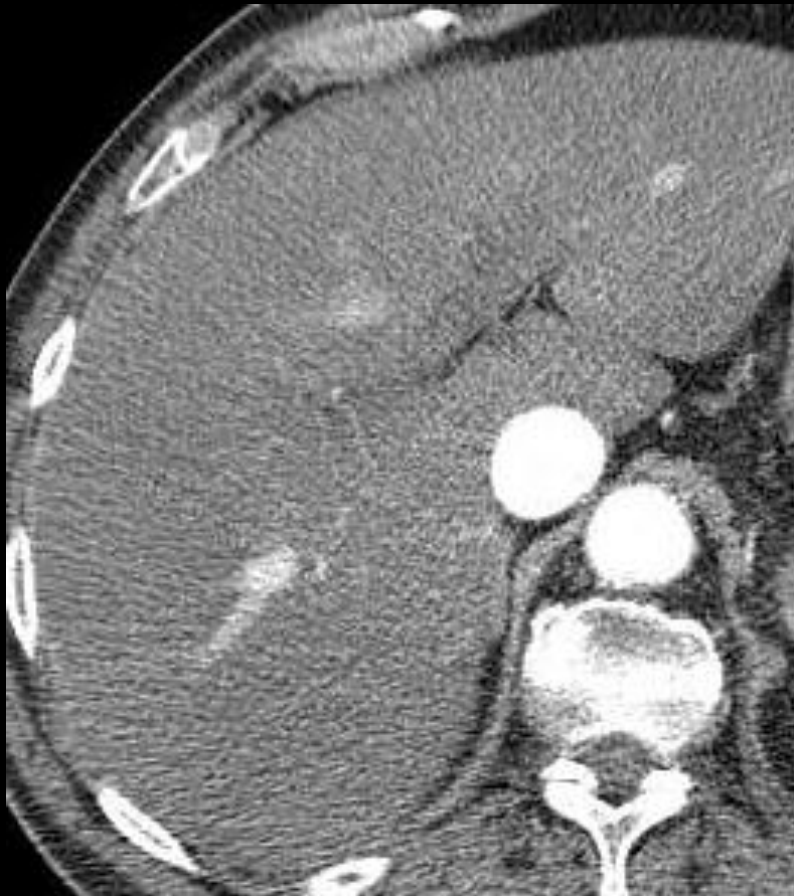Peritoneal lymphomatosis

- Distinction between carcinomatosis was made by biopsy
- Peritoneal lymphomatosis is characterized by ascites, thickened peritoneal surfaces with multifocal nodules and masses, and infiltration of mesentery and omentum. In secondary involvement of the peritoneum, the presence of extensive adenopathy may suggest the diagnosis.
- Primary lymphomas of the peritoneum are uncommon and nearly exclusively found in immunocompromised patients as it happened in the present case.

RETROPERITONEAL COMPARTMENT

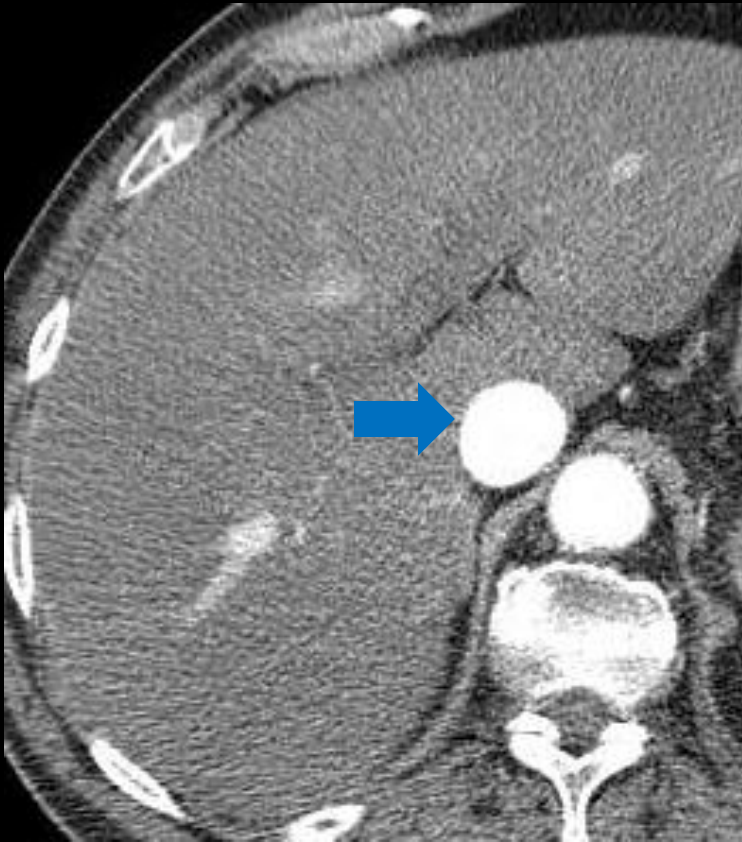
Patient 21

- Man, 76, with severe abdominal pain and a history of abdominal aortic aneurysm.
- Clinical suspicion of aneurysm rupture.

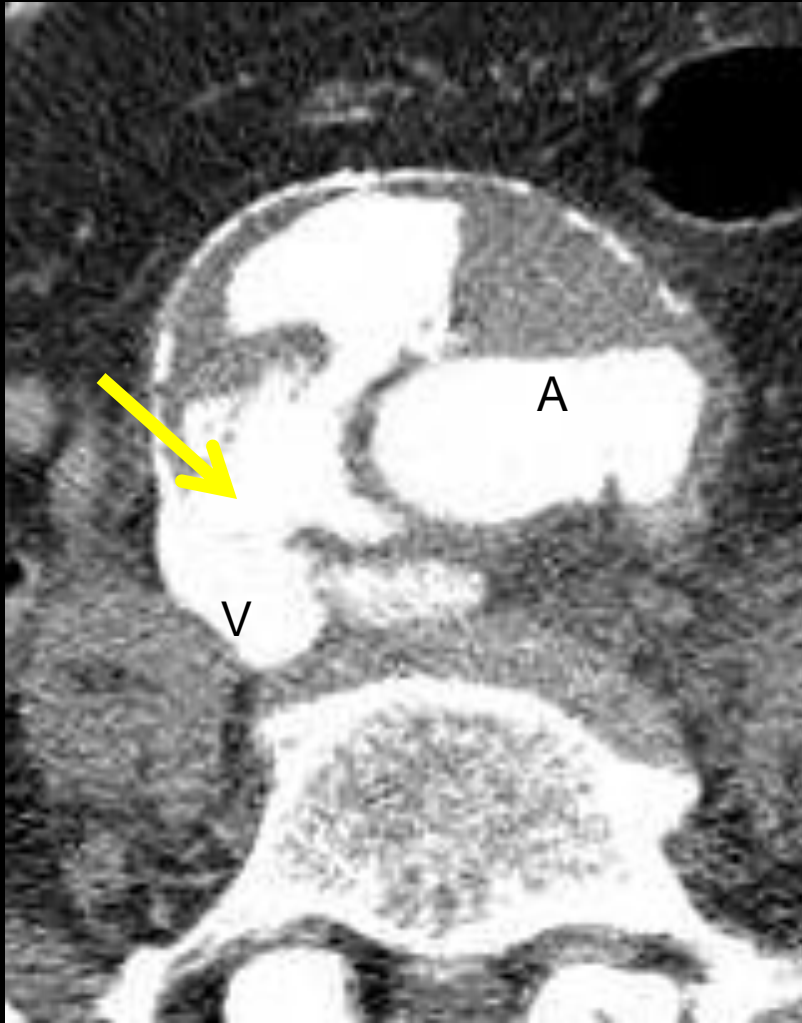


In this arterial phase image what is the bizarre finding?

What are the alternatives to explain it?



- Inferior vena cava has greater caliber than the aorta and similar attenuation
- Differential:
 - Cardiac failure
 - Aorto-cava fistula
 - Injection of contrast through a lower limb vein

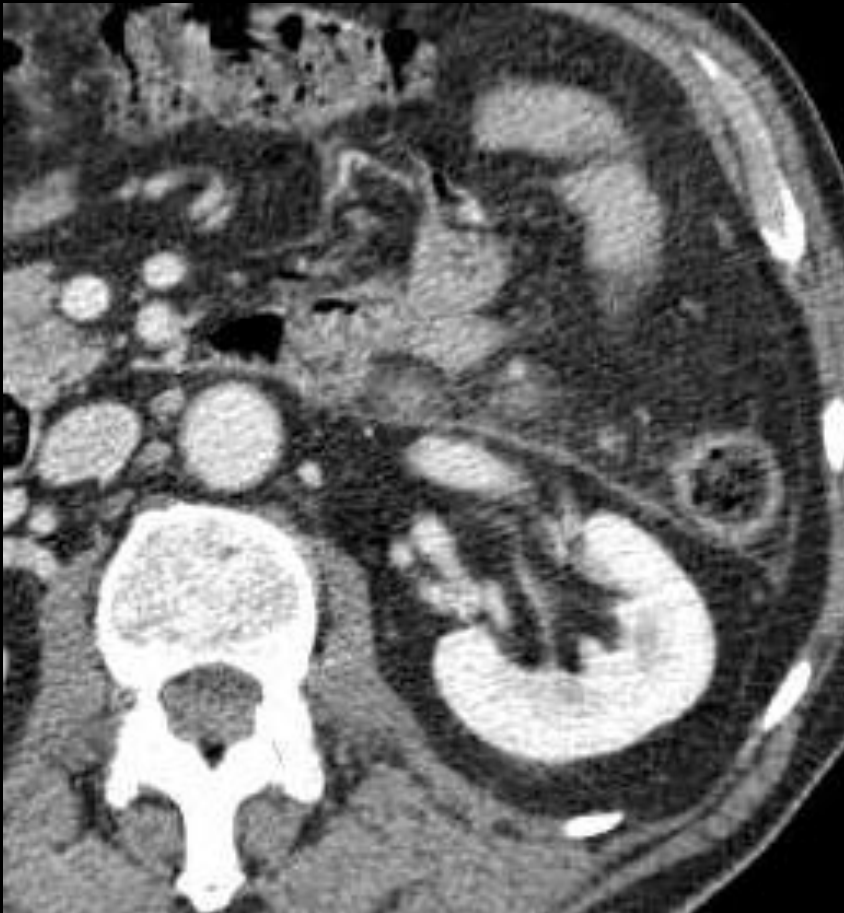

- Yellow arrow points the communication between IVC lumen and a ruptured aortic aneurysm

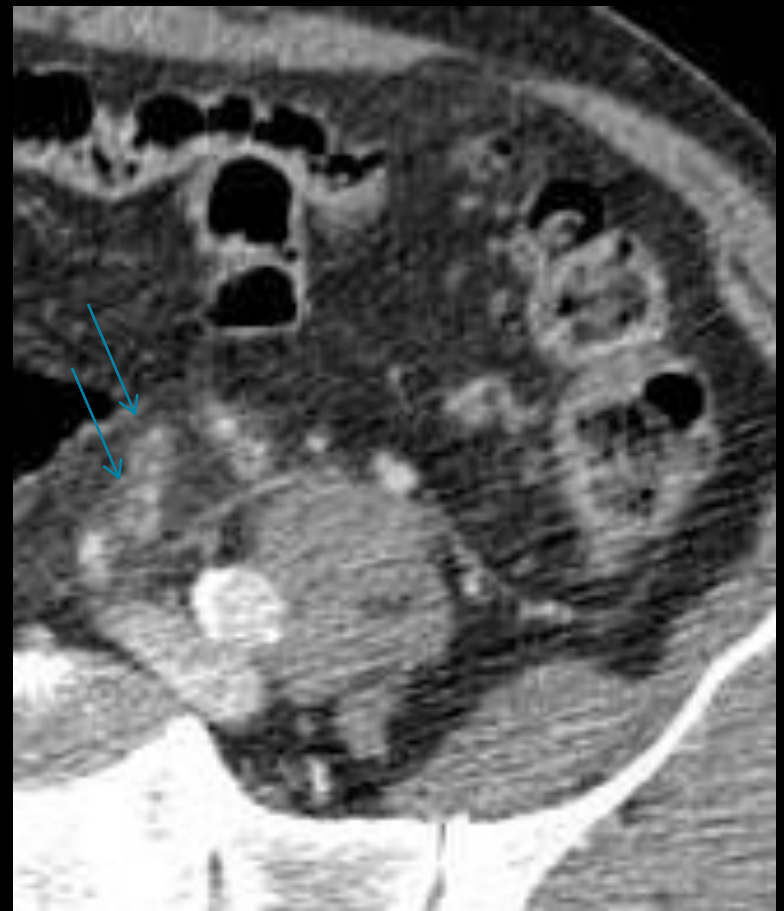
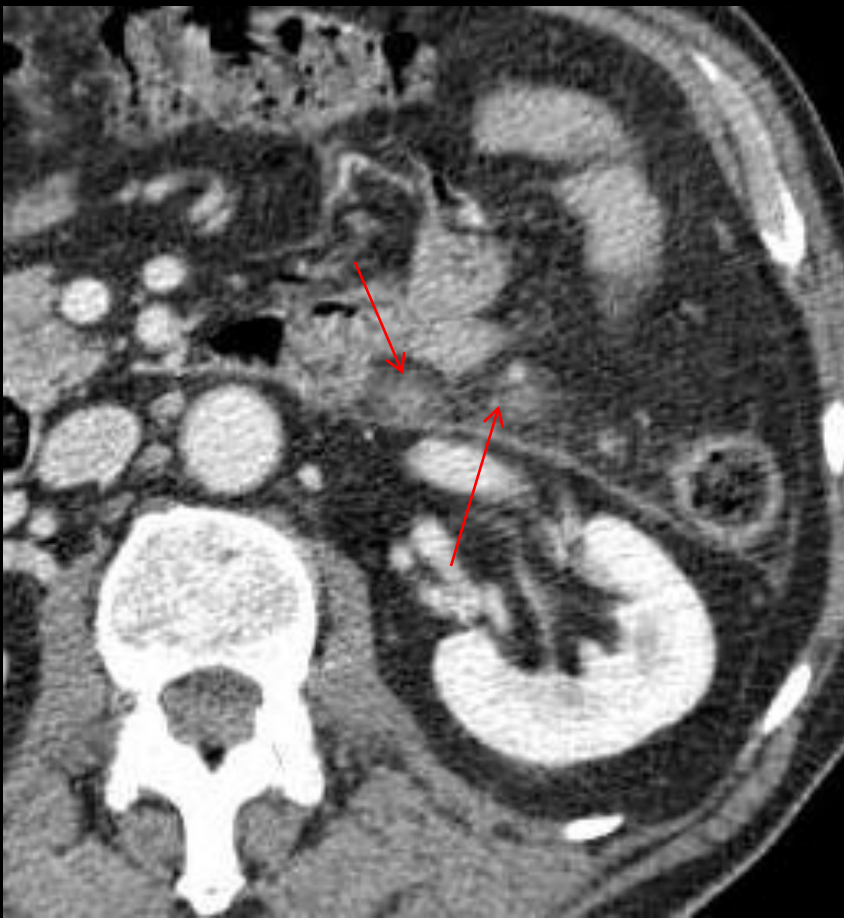Arterio-venous fistula

Case 22

- Man, 88 The pain and abdominal defense in the left quadrant and high inflammatory parameters. Clinical suspicion of diverticulitis.



- What are the pathologic changes present in this image?
- Which are predisposing factors to this problem?

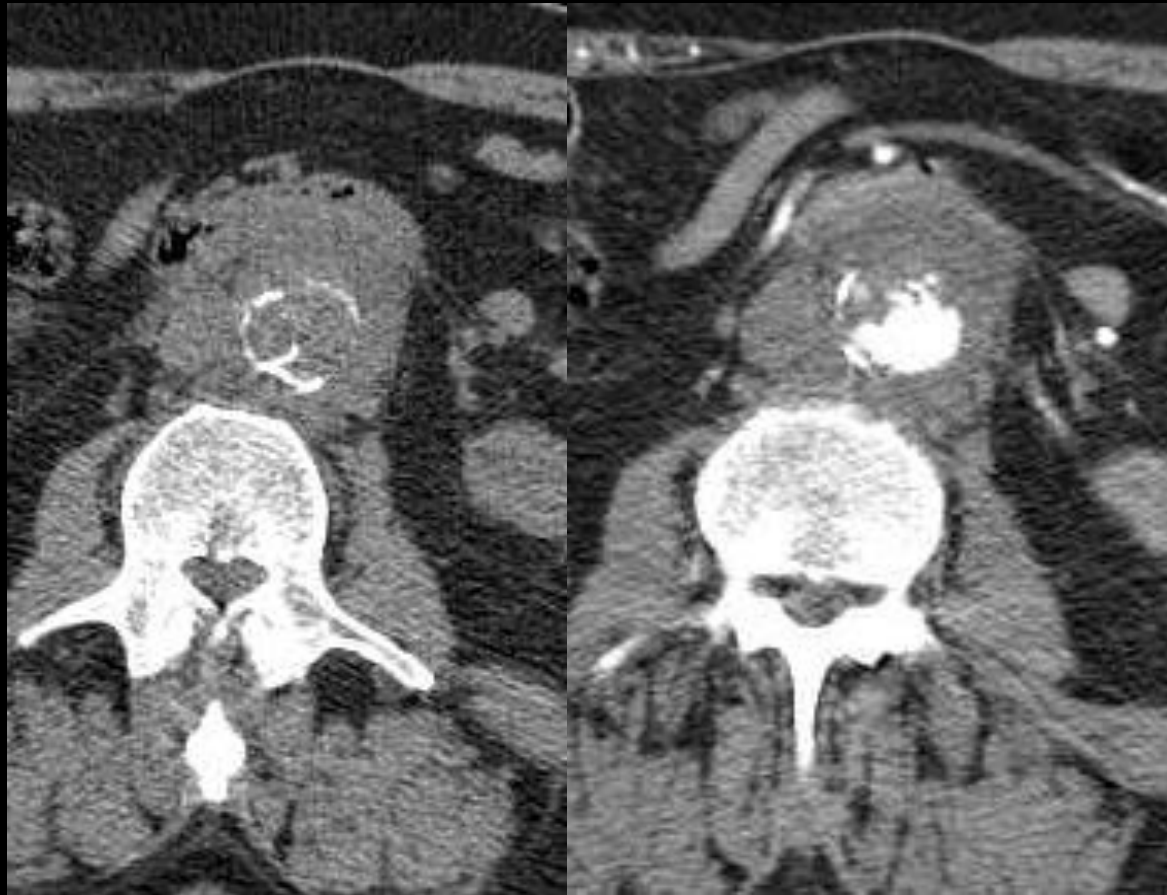

The abdominal CT study after IVC shows marked densification of fat involving the inferior mesenteric vessels (red arrow), thrombosis, wall thickening and enhancement (blue arrow) of the inferior mesenteric vein and its branches.

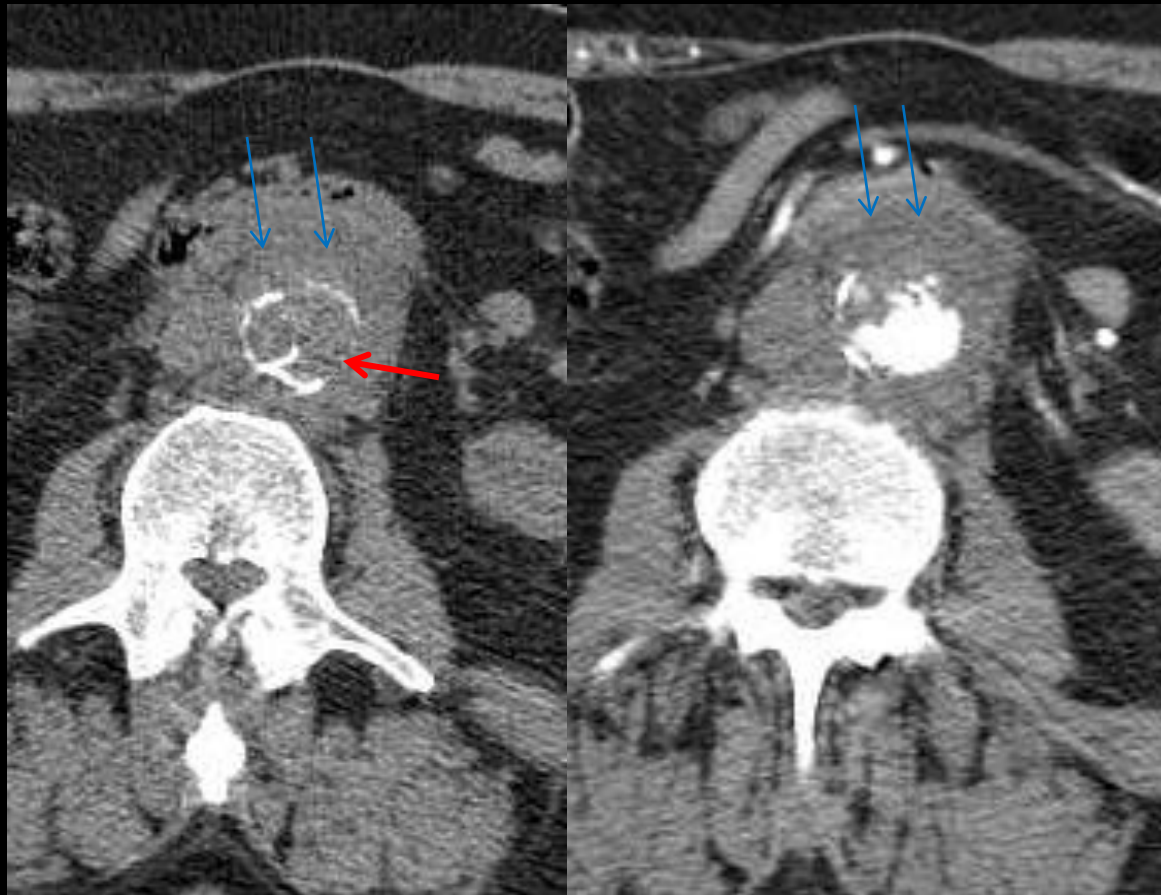Inferior mesenteric vein thrombophlebitis

Case 23

- Man, 73 A, with febrile syndrome and increased inflammatory parameters, recalcitrant to antibiotic therapy



How do you describe CT findings?



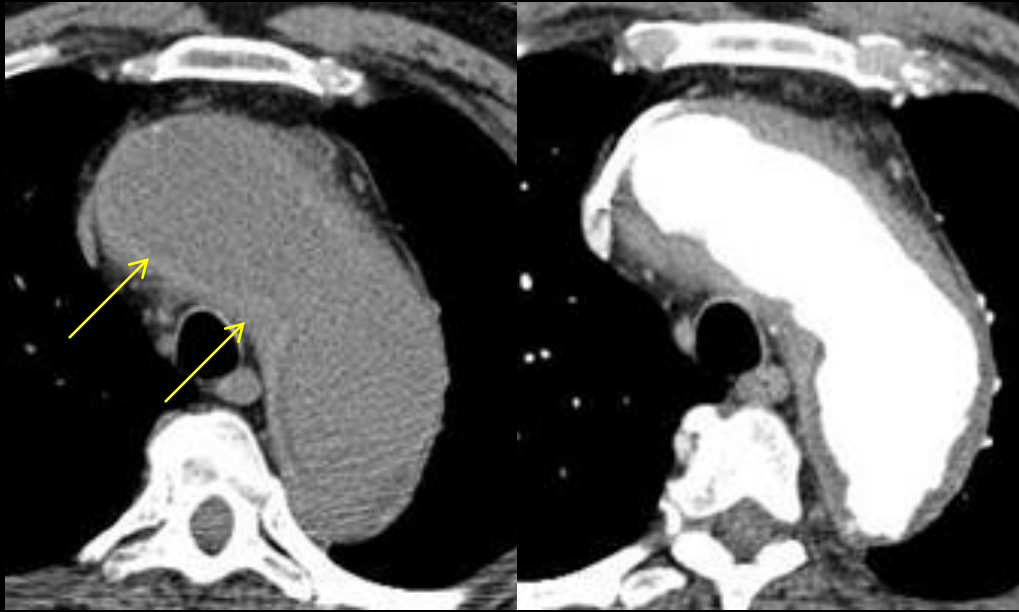
- Mass of soft tissue surrounding the infrarenal aorta (blue arrow).
- Irregularity and discontinuity of parietal calcifications of the aorta (red arrow) .

Mycotic aneurysm by Listeria

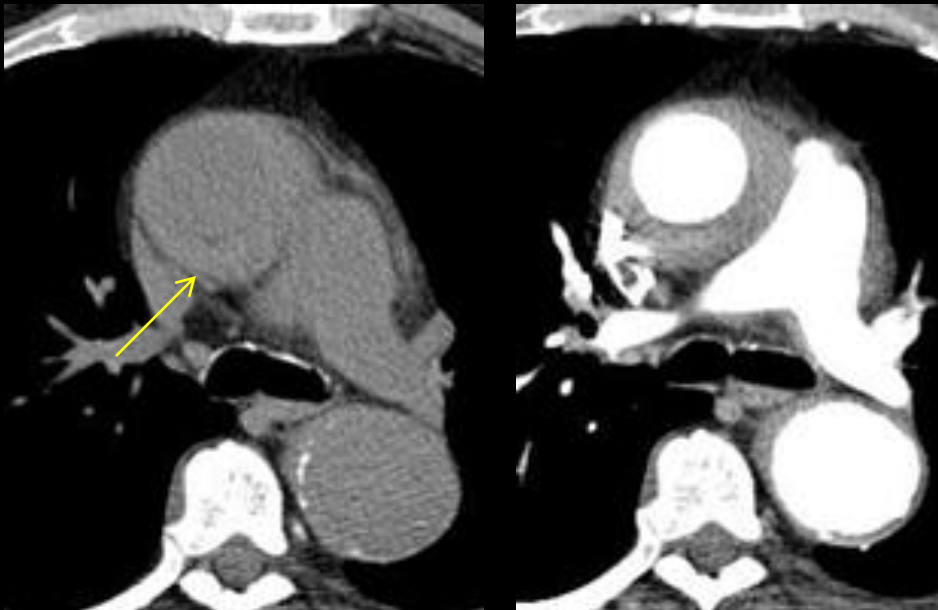
- Differential diagnosis includes periaortite and mycotic aneurysm
- In this febrile patient with bacteriemia helped in diagnosis
- Additional findings include perianeurysmal gas and adjacent vertebral body destruction.

Case 24

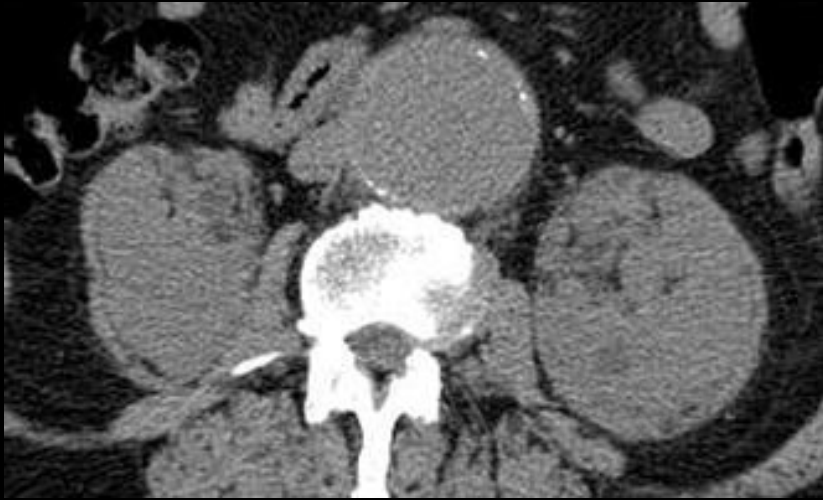- 73 years old man went to the urgency room due to thoracic pain, progressive dyspnea and easy fatigue, with worsening in the last days.
- He was an aortic aneurysm already know.
- The physical examination was normal.



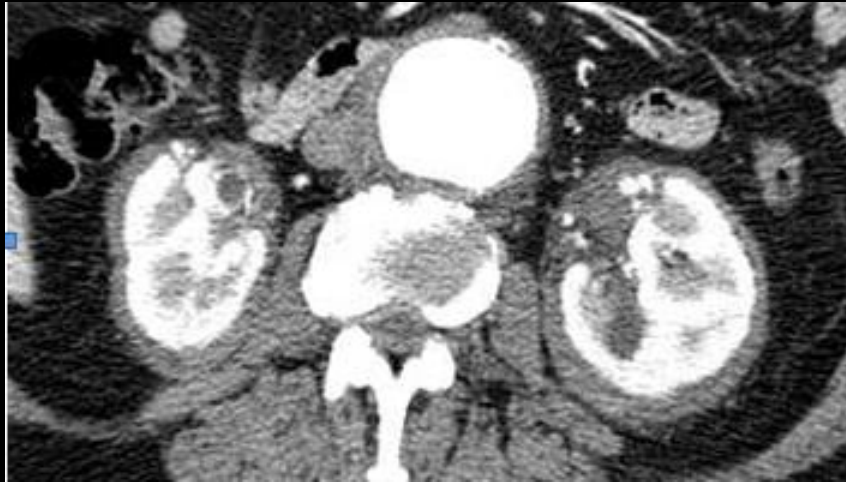
Our first impression was that the patient had a acute aortic hematoma, since we saw a hyperdense contour in aortic wall



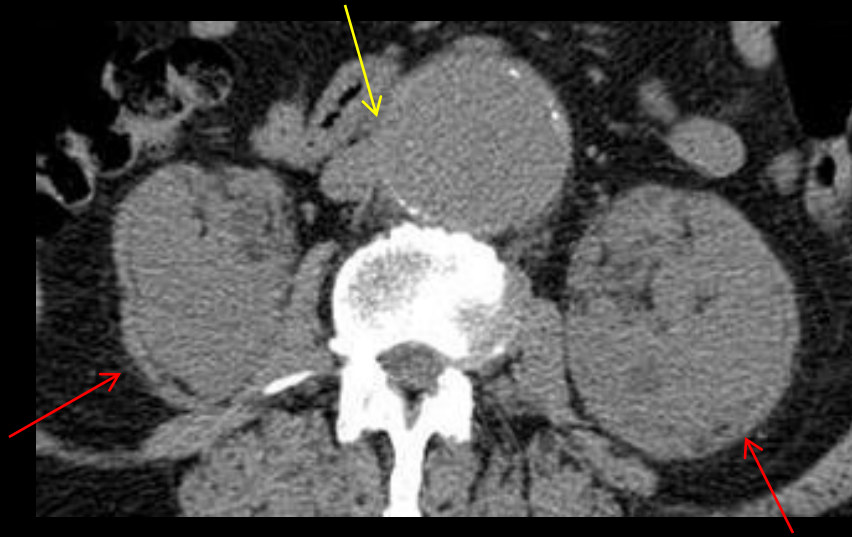Could you remember any alternative diagnosis?



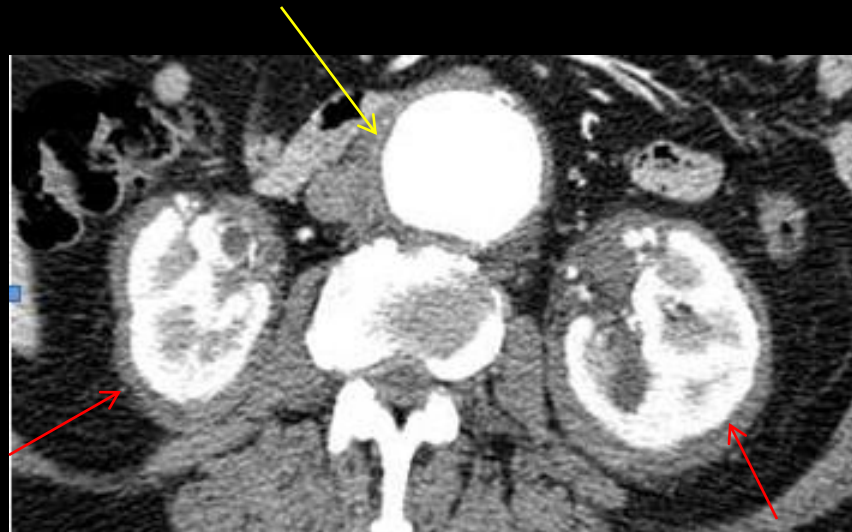For luck the technician acquired the abdomen to



How do you describe the findings?



- Periaortic tissue infiltration isodense, enhances homogeneously after iv contrast. It spared the inferior vena cava and the pelvic ureters (yellow arrow)



- There was also a bilateral and symmetric perirenal infiltration reaching the hilum – the hairy kidney – but without causing obstruction or vascular stenosis (red arrow)

Differential diagnosis:

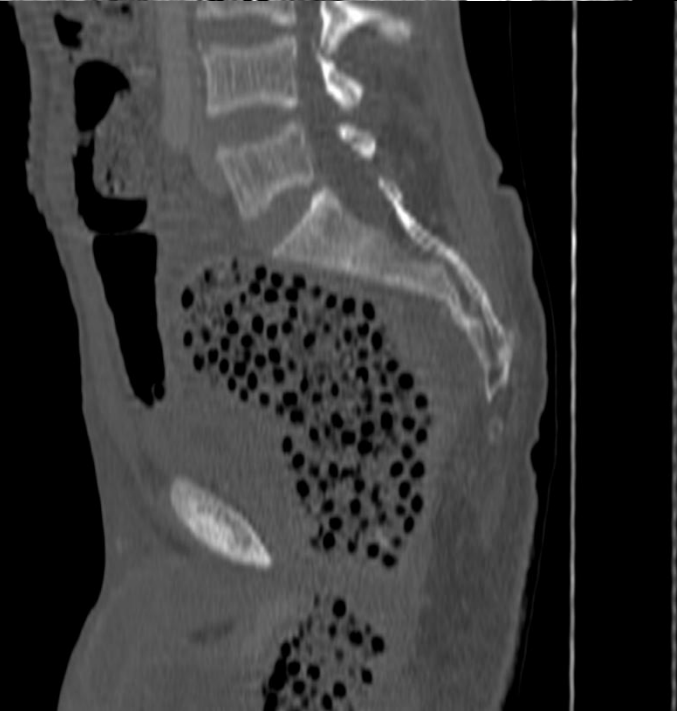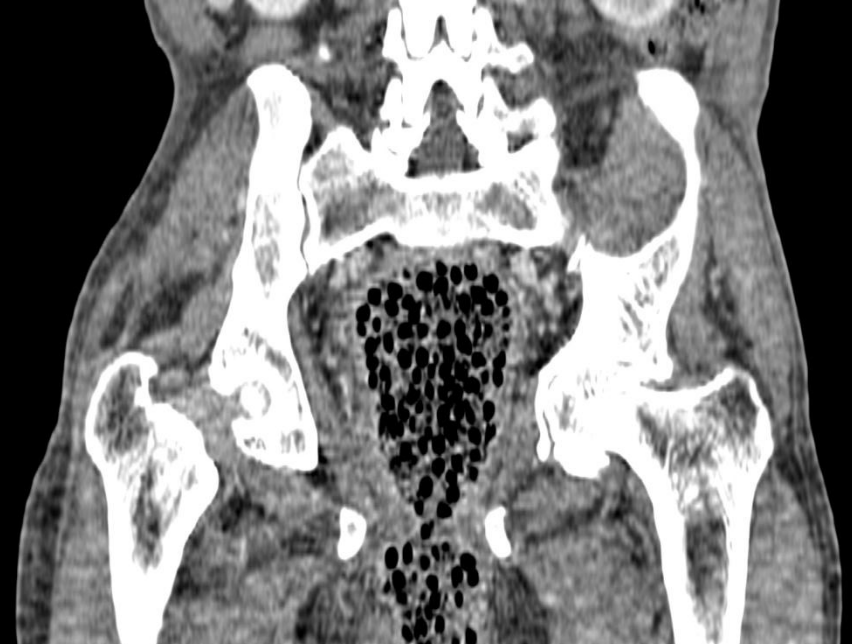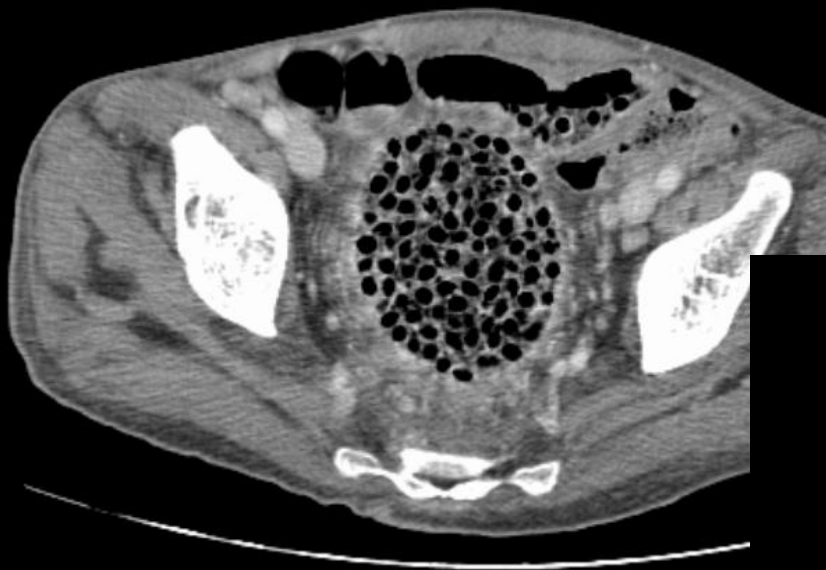
- Retroperitoneal fibrosis
- Erdheim Chester disease
- Inflammatory aneurysm
- Aortitis.
- Sarcoidosis

Erdheim Chester disease

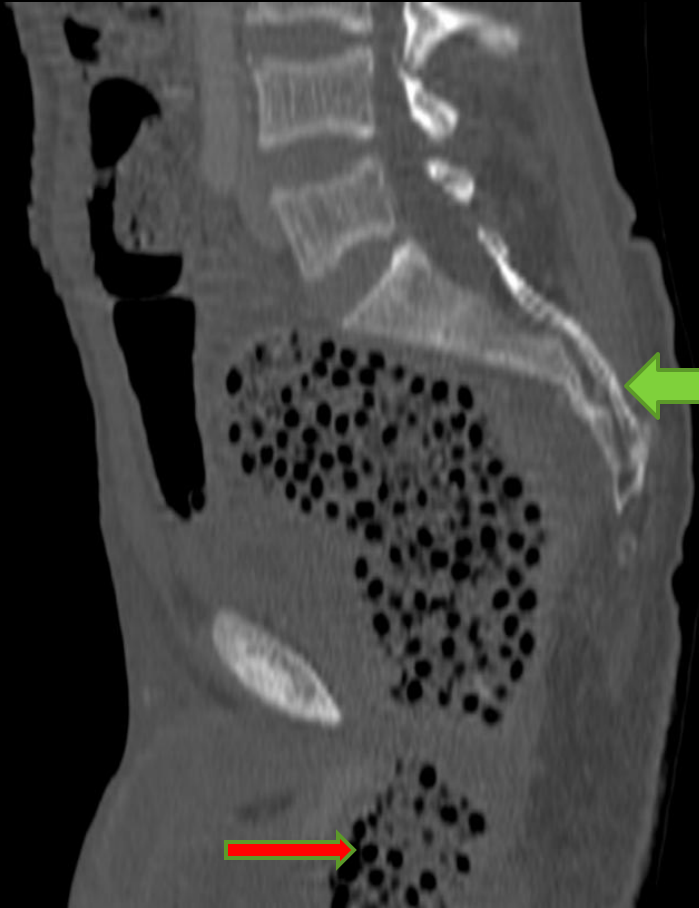
FOREIGN BODIES

Case 25

- Excruciating diffuse abdominal pain for 24 h
- History of copious meal in the night before symptoms
- Rectal examination revealed hard intra-rectal structure



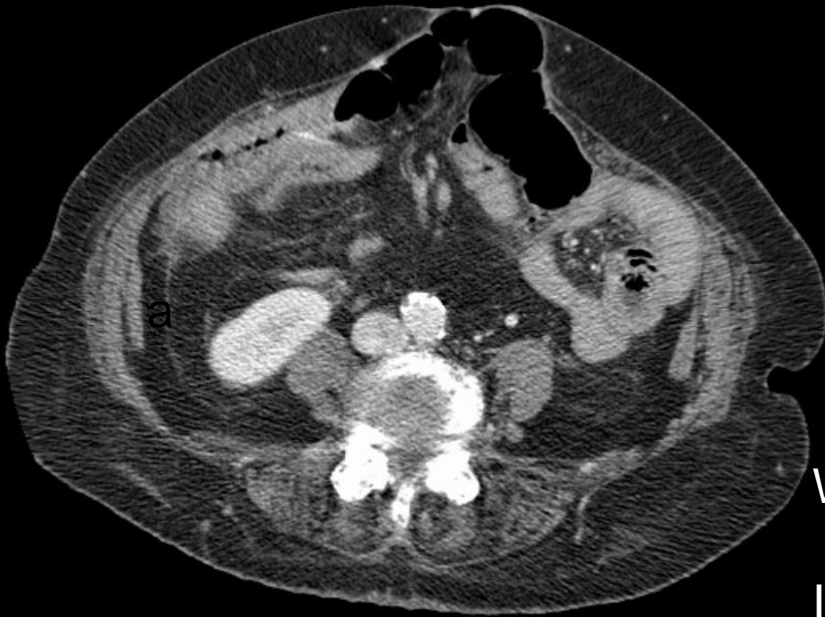
What is the cause of the fecaloma?



- Cherry pits (green arrow) impacted in the sigmoid colon and rectum caused intestinal obstruction.
- In the night before he ingested 5 Kg of cherry's
- Only when we saw the material between buttocks (red arrow), we made diagnosis (but by physical exam)
- Surgical transanal removal was needed for treatment.

Case 26

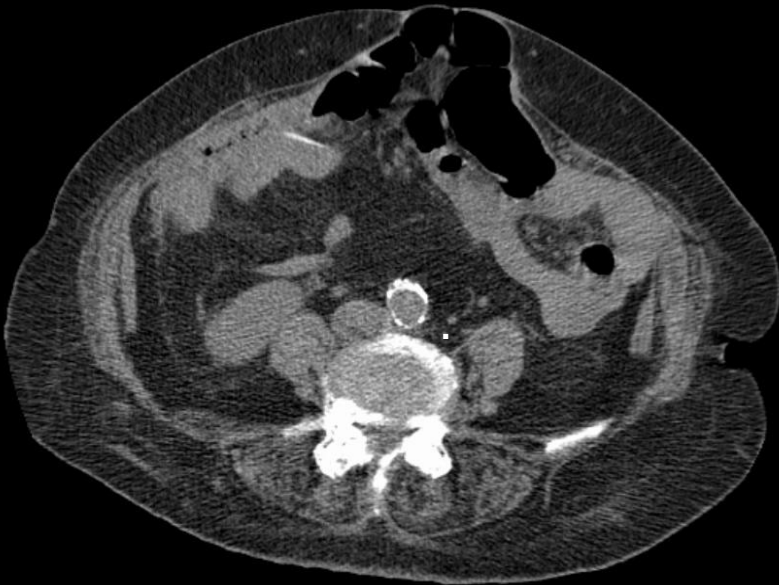- Male
- 57 years old
- Intense peri-umbilical pain
- Previous laparotomy for right hemicolectomy
- Ultrasound and abdominal plain film normal

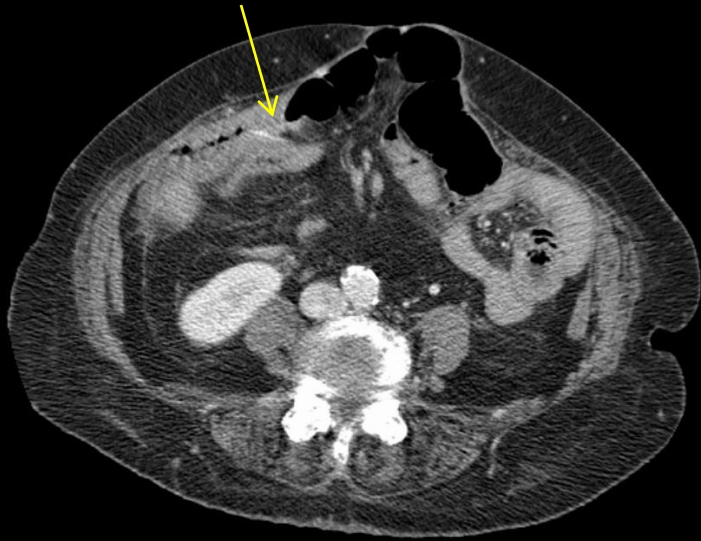


What is causing abdominal pain?

Is there bowel obstruction?

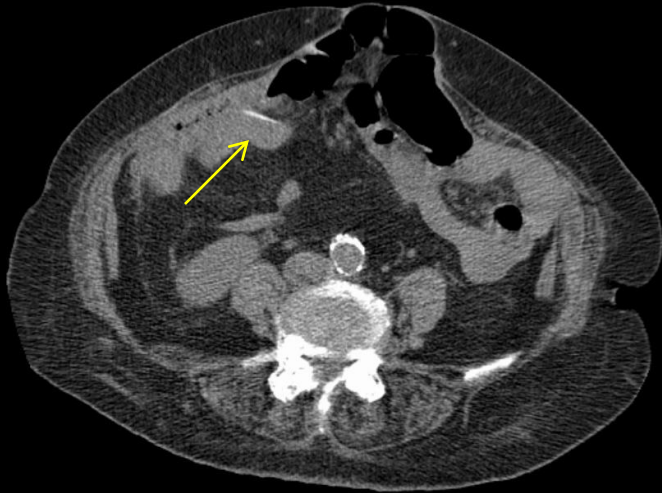
Do we see signals of abdominal inflammation?





- The surgeon at first was concerned by the possibility of obstruction caused by an adhesion, but no bowel dilatation was seen

- Then we saw what we thought to be a fish-bone, traversing small bowel wall, but without secondary signs of perforation, or inflammatory changes

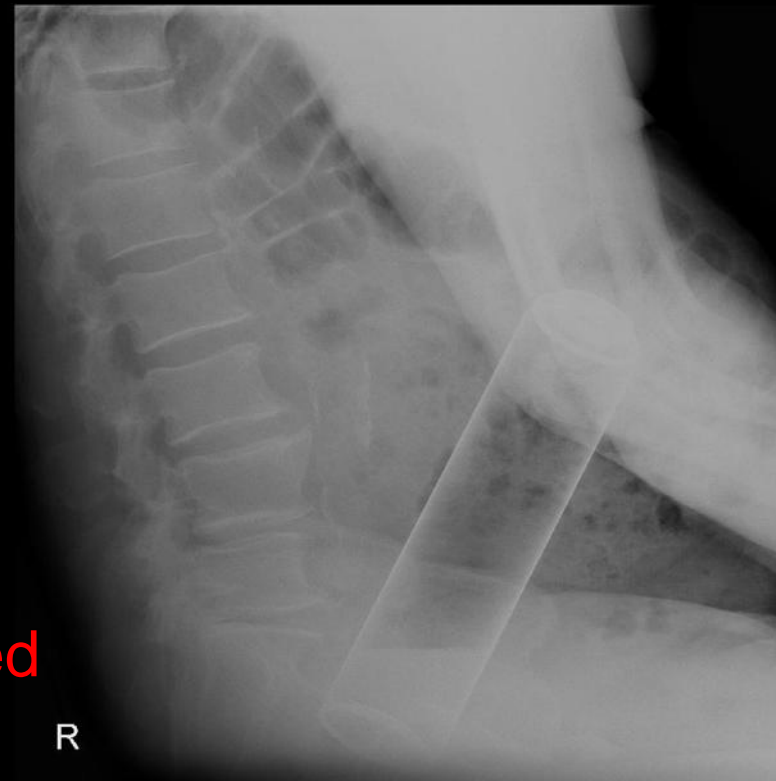
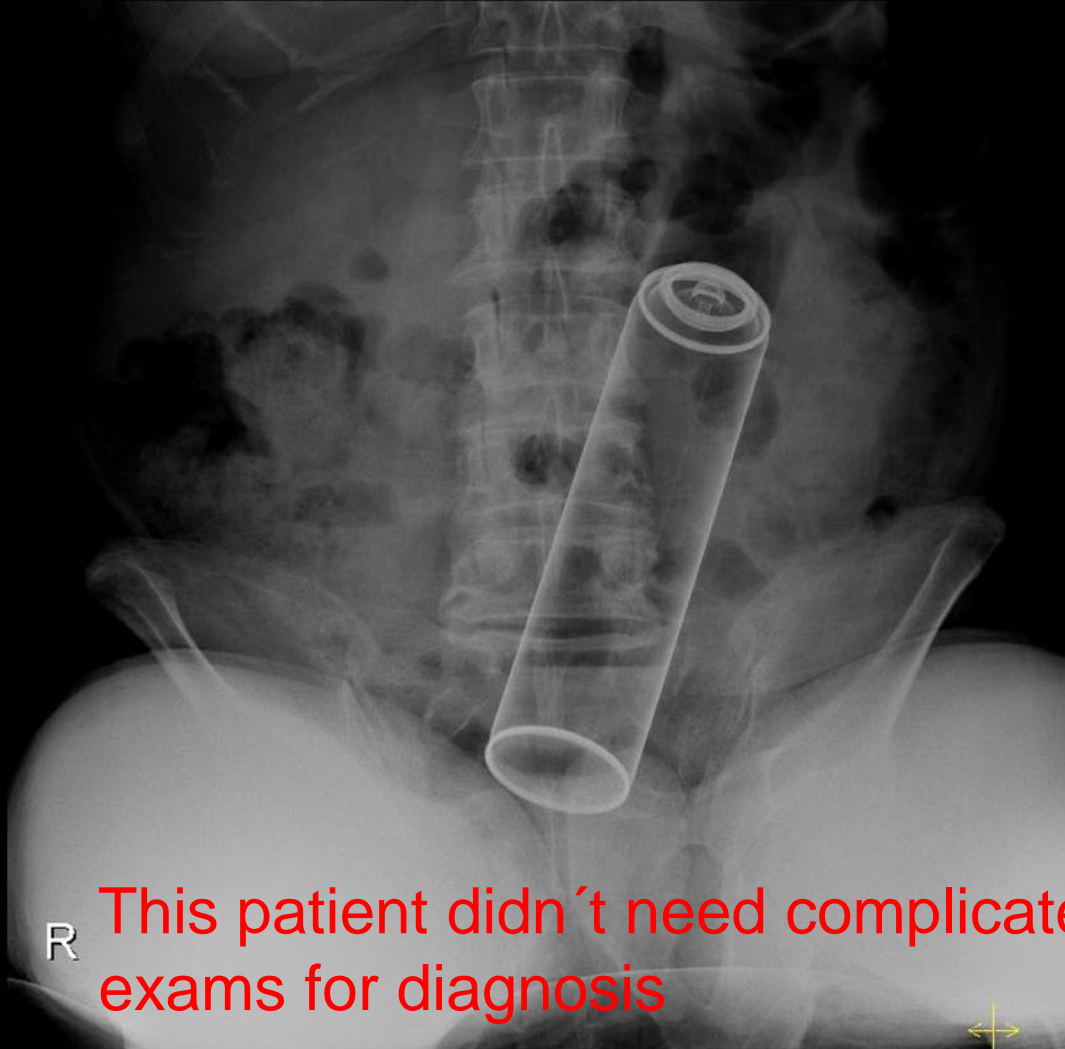


- Later the surgeon informed us, that he had extracted a toothpick from wall of terminal ileum, with minimal perforation

- We were a bit surprised since a wood object should not be hyperdense.

Yellow arrow points a high density foreign body in terminal ileum.

Case 27



Conclusion:

- In the end, after a critical analysis of my poster, I hope that colleagues will learn from my mistakes and my successes, whelping them to avoid mistakes sourced by inexperience, lack of knowledge, or incomplete observations.